

62. Toussaint HM, Beek PJ: Propelling efficiency of front-crawl swimming. *J Appl Physiol* 65:2506-2512, 1988
63. Troup JP: The physiology and biomechanics of competitive swimming. *Clin Sports Med* 18(2):267-283, 1999
64. Wadsworth DJ, Bullock-Saxton JE: Recruitment patterns of the scapular rotator muscles in freestyle swimmers with subacromial impingement. *Int J Sports Med* 18(8):618-624, 1997
65. Wakayoshi K, et al: Adaptations to six months of aerobic swim training. Changes in velocity, stroke rate, stroke length and blood lactate. *Int J Sports Med* 14(7):368-372, 1993
66. Warner JJ, et al: Patterns of flexibility, laxity, and strength in normal shoulders and shoulders with instability and impingement. *Am J Sports Med* 18(4):366-375, 1990
67. Zemek MJ, Magee DJ: Comparison of glenohumeral joint laxity in elite and recreational swimmers. *Clin J Sport Med* 6(1):40-47, 1996

*Address reprint requests to*

Edward J. Weldon III, MD  
 John A. Burns School of Medicine  
 Division of Orthopaedic Surgery  
 1356 Lusitana St.,  
 Suite 602  
 Honolulu, HI 96813

## OVERUSE INJURIES OF THE UPPER EXTREMITY IN TENNIS PLAYERS

Robert G. Marx, MD, MSc, John W. Sperling, MD, MS,  
and Frank A. Cordasco, MD, MS

It has been estimated that tens of millions of individuals play tennis in the United States.<sup>45, 56</sup> Of these, more than a half million are adolescents.<sup>27</sup> Also, a growing number of seniors continue to play tennis.<sup>50</sup> Overuse injuries of the upper limb resulting from repetitive serving and hitting are common in this sport.<sup>88</sup> A review of anatomic considerations and biomechanics unique to tennis players is presented, followed by a description of common injuries and conditions.

### BIOMECHANICS AND MUSCLE ACTIVITY IN TENNIS

Tennis has three basic strokes: the overhead or serve, the forehand, and the backhand.<sup>74</sup> In world-class tennis players, rotational velocities of 1500, 387, and 895 degrees per second, respectively, are achieved in each of these motions.<sup>43</sup> Hand speeds at ball impact in these individuals are 47, 37, and 33 miles per hour, respectively.<sup>43</sup> These values are likely much lower in less-skilled individuals, but significant forces are applied to the upper limb while playing this sport. Many factors influence the

Dr. Marx was supported by an American Academy of Orthopaedic Surgeons Health Services Research Fellowship and a Royal College of Physicians and Surgeons of Canada Detweiler Travelling Fellowship.

From the Sports Medicine and Shoulder Service, Hospital for Special Surgery, New York, New York (RGM, FAC); and the Department of Orthopedic Surgery, Mayo Clinic, Rochester, Minnesota (JWS)

CLINICS IN SPORTS MEDICINE

VOLUME 20 • NUMBER 3 • JULY 2001

439

forces generated in the upper limb, including strength, range of motion, and level of skill.

One study in 203 elite junior tennis players (age range, 11 to 17 years) demonstrated similar external rotation in both shoulders, but less internal rotation in the dominant arm (mean, 8°;  $P = 0.001$ ).<sup>21</sup> This finding was ascribed to posterior capsule or cuff tightness. Kibler et al reported similar findings in 39 members of the US Tennis Association,<sup>44</sup> along with an increase in external rotation in the dominant arm. Loss of dominant shoulder internal rotation was associated with both age and years of play.<sup>44</sup> The authors concluded that early correction of this adaptation should be considered to avoid deleterious biomechanics and potential injury. All subjects in this study were asymptomatic, however, and similar findings have been reported in asymptomatic professional baseball players.<sup>5</sup> The cause and significance of this alteration of motion in the dominant shoulders of these individuals remains unknown.

The tennis serve is composed of four stages: wind-up, cocking, acceleration, and deceleration and follow-through<sup>60</sup> (Fig. 1). Forehand and backhand groundstrokes are characterized by three stages: racquet preparation, acceleration, and follow-through.<sup>92</sup> Several studies using electromyographic analysis have defined muscle activity relating to these stages. Muscle activation in the serve and forehand is greatest for the subscapularis, the pectoralis major, and the serratus anterior.<sup>92</sup> The backhand involves largely the middle deltoid, supraspinatus, and infraspinatus.<sup>92</sup> Wrist extensor activity is predominant in all strokes, which could help explain this joint's predisposition to injury.<sup>12, 60</sup> Racket grip size, which is an important variable, had a minimal effect on electromyographic activity of these muscles.<sup>1, 53</sup> None of the wrist extensors showed increased activity in the single-handed backhand compared with the double-handed backhand.<sup>25</sup> Therefore, injury to the extensor origin is more likely related to flawed stroke mechanics than to the use of the single-handed backhand stroke.<sup>26</sup>

Cohen et al found a correlation between both strength and flexibility and serve velocity.<sup>13</sup> Although technique obviously is important, strength is important for performance. Ellenbecker and Roetert noted that the external rotators of elite junior tennis players tend to tire faster than the internal rotators during isokinetic testing at 90° of abduction.<sup>20</sup> In another study, college tennis players had significant increases in strength in internal rotation at 90° of abduction in their dominant shoulders, with no difference in external rotation power.<sup>11</sup>

Upper limb flexibility and muscle strength are critical elements for tennis players. Sound stretching programs and the appropriate use of weight training and isokinetic training can reduce the risk of overuse injury and potentially improve performance.<sup>14, 29, 59</sup>

## SHOULDER INJURIES

The tennis player is predisposed to overuse injuries of the shoulder because of the repetitive nature of the game. Biomechanical comparisons

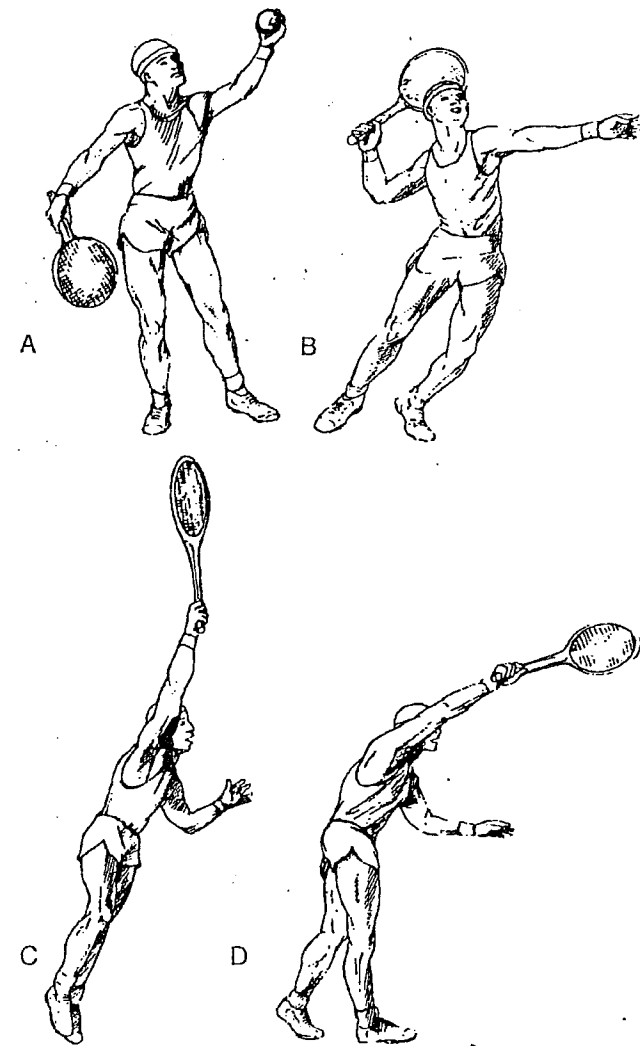


Figure 1. Sequence of the tennis serve. A, Windup; B, Cocking; C, Acceleration; D, Deceleration and follow-through. (From Field LD, Altchek DW. Tennis Injuries. In Hawkins RJ, Misamore GW; with permission [eds]: *Shoulder Injuries in the Athlete*. New York: Churchill Livingstone, 1996:403-416.)

between the overhead thrower and tennis player provide insight into possible mechanisms of injury.<sup>51, 75</sup> Tennis differs from other sports, however, owing to the use of a racquet. The lever arm and weight of the racquet, which add significant power to the tennis stroke, also markedly increase stress on the shoulder and the potential for injury.<sup>75</sup> The tennis player must balance maximal force output with maintenance of shoulder stability.

Overuse and muscular fatigue in the tennis player can decrease efficiency of the dynamic shoulder stabilizers and cause secondary injury to the static shoulder stabilizers. Subsequent plastic deformation of the static stabilizers then can result in increased instability. Altered shoulder mechanics can lead to secondary impingement and the potential for the development of rotator cuff tears.<sup>58</sup> Therefore, early recognition of shoulder overuse injuries is essential for the effective treatment of the tennis player.

Evaluation of shoulder pain in the tennis player begins with an accurate history. Understanding the chronology of symptoms, prior treatment, and training schedule is essential. The relative time practicing different strokes should be elicited,<sup>52</sup> especially the specific amount of time engaged in overhead strokes such as the serve, volley, and overhead smash. Priest noted that competitive tennis players most commonly cited the service and the overhead smash as the strokes that were responsible for the onset of pain.<sup>80</sup> Inquire about neurosensory changes (such as radiating numbness) and mechanical complaints such as catching and clicking. A "dead arm" sensation can be associated with instability.<sup>90</sup> Referred pain from spine pathology always should be considered. Additionally, a thorough history of previous shoulder instability should be obtained.

The physical examination begins with inspection of the standing patient to evaluate for asymmetry and atrophy. It is essential to examine and compare both shoulders. One may observe the postural change frequently seen in tennis players, termed *tennis shoulder*, depression of the dominant shoulder with the appearance of scoliosis,<sup>48, 81</sup> first described by Priest and Nagel.<sup>81</sup> Tennis players also can present with atrophy of the biceps and triceps muscles and hypertrophied forearm muscles.<sup>52</sup> Observe the posterior aspect of the shoulder to evaluate the scapular stabilizers, check for asymmetry, and assess scapular protraction. Systematic palpation of the shoulder and upper extremity should include the sternoclavicular and acromioclavicular joints, clavicle, long head biceps tendon, deltoid insertion, and greater tuberosity. Additionally, the scapula and acromion should be palpated. Medial scapular bursitis has been described as a potential cause of posterior pain.<sup>88</sup>

Range of motion of both shoulders should be recorded and the relative contributions of scapular and glenohumeral motion assessed. Typically, shoulder internal rotation is lost and external rotation is increased. The underlying cause of restricted internal rotation is usually posterior capsular tightness. These findings also are seen typically in throwers.<sup>8</sup> Harryman et al demonstrated in a cadaveric model that

posterior capsule tightness could result in increased anterior translation.<sup>34</sup> Elevation, extension, external rotation, internal rotation, and abduction strength are tested. Strength testing should be performed for side-to-side comparison. The supraspinatus is tested with the arm elevated to 90° in the scapular plane with internal rotation of the humerus. The lift-off test checks the integrity of the subscapularis.<sup>25</sup>

Glenohumeral instability testing begins with the patient seated. The sulcus sign determines the degree of inferior translation. With the patient supine, anterior apprehension testing is performed with the shoulder in abduction and external rotation. A posteriorly directed pressure then is applied with the relocation test to assess whether this improves apprehension symptoms and pain. Posterior apprehension is tested in flexion and internal rotation. The load-and-shift test is performed in the supine position with attention directed toward the amount of motion present, the firmness of the endpoint, and the elicitation of pain or instability. Additionally, when examining for internal impingement of the posterior rotator cuff against the posterior-superior glenoid rim, the shoulder is externally rotated and abducted more than 90°.<sup>15, 97</sup>

Subacromial impingement is assessed while the patient is seated. First, the shoulder is elevated in the plane of the scapula while the scapula is stabilized. Pain constitutes a positive impingement sign, as described by Neer.<sup>63</sup> Hawkins described an impingement sign in which the humerus is placed in 90° of flexion, the elbow is flexed to 90°, and then the humerus is internally rotated.<sup>35</sup> The crossed-arm adduction test is performed to elicit pain associated with acromioclavicular joint pathology.

Speed's test and Yergason's test are useful to isolate the biceps as a cause of pain. Speed's test is performed by having the patient attempt flexion of the arm with the elbow in 30° of flexion and the forearm supinated. The test is considered positive if pain is elicited in the bicipital groove.<sup>64</sup> Yergason's test is resisted supination of the forearm with the elbow flexed.<sup>100</sup> O'Brien's test is effective in assessing pathology originating in the superior labral or long head of the biceps tendon.<sup>68</sup>

A complete neurovascular examination should begin with assessment of the cervical spine. Restricted motion and pain can indicate arthritis or cervical disk disease.<sup>28</sup> In addition to determining the range of motion, provocative maneuvers should be performed to see if they reproduce symptoms. Thoracic outlet syndrome also can cause pain and neurologic changes.

Radiographic evaluation should include axillary and anteroposterior and lateral views of the scapula. Do not overlook the possible presence of an os acromiale as a cause of pain in tennis players.<sup>9</sup> In addition to these standard radiographs, magnetic resonance (MR) imaging has proved to be a powerful adjunct in the diagnosis of shoulder disorders in athletes. Improved techniques allow better visualization of labral, chondral, and rotator cuff pathology.

The differential diagnosis most commonly includes subacromial impingement, glenohumeral instability, internal impingement, and rota-

tor cuff tendinosis or tear. In addition, other common causes of shoulder pain worth consideration include acromioclavicular arthritis, labral pathology, biceps pathology, and chondral injury. Lastly, consider those disease processes that can refer pain to the shoulder, including cervical spine disease and thoracic outlet syndrome.

The treatment of overuse injuries in tennis players relies primarily on proper rehabilitation. An important aspect is educating the patient with regard to altered shoulder mechanics and discussing how a thorough rehabilitation program can be effective.<sup>19</sup> The goal of treatment is to restore normal shoulder mechanics and return the player to pain-free function.

Asynchronous muscle firing also can result in scapular dysfunction, including winging, decreased protraction, or retraction.<sup>75</sup> Impaired scapular protraction has been cited as a potential contributing factor to subacromial impingement. Therefore, the scapula and scapular-stabilizing muscles, including the rhomboids, serratus anterior, trapezius, and levator scapulae, must be addressed in a rehabilitation protocol.<sup>75</sup> Additionally, rehabilitation of the larger back muscles, such as the latissimus dorsi, should be incorporated into a rehabilitation protocol because they decrease supraspinatus tendon overload during the deceleration phase of the serve.<sup>95</sup>

Failure of a properly supervised rehabilitation program in conjunction with well-defined pathology is a potential indication for surgical intervention. McCann and Bigliani reported that the two most common causes of shoulder pain in the tennis player are impingement syndrome and glenohumeral instability.<sup>57</sup> They noted that patients with the diagnosis of subacromial impingement who do not respond to motion and strength restoration are candidates for anterior acromioplasty and appropriate treatment of the associated rotator cuff pathology. With respect to glenohumeral instability, the authors suggested that patients who fail to improve with rotator cuff and scapular-muscle strengthening are candidates for repair of the capsulolabral complex.

Rotator cuff tears in tennis players can be repaired successfully, and the athlete has a good chance of returning to previous level of play. Bigliani et al reported on the results of rotator cuff repair and acromioplasty in 23 tennis players.<sup>4</sup> There were eight small tears (<1 cm), five moderate tears (1 to 3 cm), two large tears (3 to 5 cm), and eight massive tears (>5 cm). At a mean follow-up of 42 months, the authors reported that 19 patients (83%) achieved a good to excellent result and were able to return to their presymptomatic level of play without pain.

Internal impingement of the rotator cuff on the posterior-superior labrum has become an increasingly recognized disorder in overhead athletes. These patients typically do not have a frank history of shoulder instability manifested by dislocation. Subtle shoulder instability can lead to secondary impingement, however.<sup>15, 40, 46, 58, 97</sup> The initial pain usually is manifest during the late cocking and early acceleration phases of throwing or serving. Rotator cuff tears usually are located on the articular surface of the posterior supraspinatus or the anterior infraspinatus, or

both. Additionally, the posterosuperior glenoid labrum can demonstrate pathologic changes associated with the internal impingement.<sup>2, 15, 40, 97</sup> Treatment of internal impingement must address any glenohumeral instability and typically begins with a rehabilitation program. Patients who fail to improve with rehabilitation could be candidates for arthroscopic labral and rotator cuff debridement and, in certain cases, shoulder stabilization.<sup>15, 40, 97</sup> Recently, there has been much discussion of treating glenohumeral instability with thermal energy. Publications have supported the underlying basic science of thermal shrinkage.<sup>36, 55, 62, 69, 98</sup> Although radiofrequency or laser thermal energy may have a role in the treatment of tennis athletes with shoulder instability or internal impingement, few short-term clinical studies and no long-term outcomes analyses are available yet to formulate clear indications for their use.

## ELBOW INJURIES

Lateral epicondylitis is the most common cause of elbow symptoms in tennis players,<sup>14</sup> but other conditions of the elbow also are encountered. Lateral epicondylitis is reviewed, followed by an overview of other disorders of the elbow seen in tennis players, including medial epicondylitis and medial instability.

"Tennis elbow" is the colloquial term for lateral epicondylitis. Despite the name, the syndrome does not involve an acute inflammatory lesion.<sup>49, 67</sup> Sometime in their career, approximately half of individuals who play tennis will suffer from tennis elbow.<sup>56</sup> Leading with the elbow on the backhand side and failing to shift body weight and swing from the shoulder are implicated as technique causes of lateral tennis elbow.<sup>48</sup> Increased vibration loads in less skilled players likely plays a role, as does racket weight. A large racket head and a higher resonance frequency of the racket reduce arm vibration.<sup>37</sup>

The onset of pain in this condition is usually insidious, although some patients have a history of a traumatic event. Physical findings in tennis elbow include tenderness at the origin of the extensor carpi radialis brevis and discomfort with passive volar flexion and resisted wrist extension. Many patients also have pain with grasp. Radiographs (anteroposterior, lateral, and radiocapitellar views) are recommended to rule out osseous pathology.<sup>7</sup> MR imaging also can be used to confirm this diagnosis.<sup>78</sup>

Many treatments have been described for tennis elbow, although little scientific evidence demonstrates that nonoperative modalities influence the long-term natural history of this disorder.<sup>7</sup> Acupuncture,<sup>30</sup> extracorporeal shock wave therapy,<sup>69</sup> ultrasonography,<sup>32</sup> corticosteroid injection,<sup>79</sup> bracing, exercise,<sup>70</sup> stroke correction,<sup>39</sup> and low-energy laser<sup>31, 33</sup> all have been described for the treatment of lateral epicondylitis with varying success rates. Boyer concluded that scientific data are inadequate to support the use of one treatment over another. Several surgical techniques have been devised to treat this condition.<sup>24, 47, 76, 96</sup>

The basic principle is to release the extensor carpi radialis brevis origin from the lateral epicondyle, with or without excision of the pathologic tissue.<sup>65, 66</sup> Most authors report success rates for this procedure at 70% to 80%.

Medial epicondylitis also occurs in tennis players, although less often than lateral epicondylitis.<sup>14, 23</sup> Medial epicondylitis must be differentiated from other causes of medial elbow pain in these athletes, such as medial collateral ligament insufficiency and ulnar neuropathy. Medial collateral ligament injury is far more common in baseball players; however, it also is seen in tennis players.<sup>14, 42</sup>

## WRIST INJURIES

Overuse injuries of the wrist are common in tennis players,<sup>84</sup> likely because of the amount of motion at this articulation that is involved in the tennis stroke.<sup>84</sup> Although most wrist injuries are secondary to overuse, direct trauma or an acute rotational episode can lead to wrist pain in tennis players. Therefore, it is important to ascertain the exact mechanism of injury, if appropriate, as well as how long the symptoms have been present and whether they have progressed. This section reviews the pertinent physical examination findings, and the clinical conditions that are particularly relevant to these athletes.

Physical examination should include palpation of the entire carpus and, more specifically, the scapholunate, triquetrolunate, and distal radioulnar and ulnocarpal joints. The hook of the hamate and the extensor and flexor tendons should be palpated. DeQuervain's tenosynovitis is not uncommon in tennis players, and the Finkelstein test to evaluate the first dorsal extensor compartment is often helpful. In the setting of acute trauma, the distal radius and the anatomic snuffbox should be examined for a fracture of the radius or scaphoid, respectively. Plain radiographs should be obtained routinely. Neutral rotation posteroanterior and lateral and oblique views are recommended. MR imaging is useful to confirm soft tissue injuries of the wrist, such as tears of the scapholunate ligament and the triangular fibrocartilage complex.<sup>72</sup>

The most common tendinitis in racquet sports is DeQuervain's tenosynovitis.<sup>77</sup> This involves inflammation of the tendons of the abductor pollicis longus and extensor pollicis brevis as they pass through a fibro-osseous tunnel at the level of the radial styloid. Ulnar deviation, particularly with grasp, can lead to inflammation and pain in this area. Finkelstein's test is positive if ulnar deviation of the wrist with the patient's thumb tucked into the first reproduces the pain. Splinting and nonsteroidal anti-inflammatory medication are usually successful in relieving symptoms. Should these fail, corticosteroid injection can be used; in rare cases, surgical release is required.<sup>72</sup> Tendinitis of the extensor carpi ulnaris tendon is also fairly common, and recurrent dislocation of this tendon has been reported in tennis players.<sup>83</sup> Surgical reconstruc-

tion of the sixth extensor compartment fibro-osseous tunnel is recommended for the latter condition.<sup>72, 83</sup>

Ulnar-sided wrist pain is a common complaint in tennis players. As discussed, this is frequently due to inflammation of the extensor carpi ulnaris tendon, although it also can be related to flexor carpi ulnaris tendonitis. The combination of impaction and rotation that occur in the tennis stroke can lead to triangular fibrocartilage complex injury. Clinically, the patient has pain in the area of the ulnar styloid that worsens with loading of the ulnocarpal joint. Radiographs are negative, although the condition is associated with positive ulnar variance. MR imaging is useful to confirm the diagnosis. If nonoperative management with splinting, rest, and nonsteroidal anti-inflammatory medication is not successful, arthroscopic debridement or repair is indicated.<sup>71, 73</sup>

Fracture of the hook of the hamate is an injury seen less commonly in tennis players.<sup>94</sup> When the grasp is relaxed or the centrifugal force of swinging the racket overcomes the grasping power, the butt end of the handle can strike and fracture the hook. The history is useful to determine whether the pain was first experienced while swinging the racket. The patient may be able to grip the racket, but has difficulty swinging it. A carpal tunnel view radiograph is best to diagnose this injury.<sup>94</sup> Computed tomography is used to confirm the fracture. The fracture can be treated with plaster immobilization if diagnosis has not been delayed. Many authors recommend early excision of this fragment, however, as it will often go on to nonunion despite proper immobilization.<sup>94</sup> Displaced fractures are best treated with excision to avoid this complication.<sup>87</sup> If unrecognized, this injury can progress to a painful nonunion, which also can be successfully treated with excision.<sup>10</sup> Avascular necrosis has been reported after this injury.<sup>22</sup>

## OTHER INJURIES

The repetitive loading of the upper extremity affects the bones of the upper limb as well as the soft tissues. The bone mineral density of the dominant upper limb is significantly higher than the nondominant arm of tennis players.<sup>38, 41</sup> Despite this favorable effect of repetitive loading from tennis on the skeleton, stress fractures have been reported at the ulna,<sup>3, 6, 83, 101</sup> humerus,<sup>86</sup> index metacarpal,<sup>61, 99</sup> distal radius,<sup>54</sup> and acromion.<sup>91</sup> Most of the reported cases of ulnar stress fractures were in the nondominant arm of patients who employed a two-handed backhand.<sup>3, 6, 83, 101</sup> It is important to bear this diagnosis in mind when evaluating these athletes, particularly females who fit the female athlete triad of eating disorder, amenorrhea, and osteoporosis.<sup>16-18</sup>

Tennis players can develop symptomatic entrapment of the ulnar, radial, posterior interosseous, or median nerves about the elbow.<sup>14</sup> Nerve palsies involving the proximal radial nerve (high radial nerve palsy) and the long thoracic nerve also have been reported in tennis players secondary to overhead serving.<sup>82, 93</sup>

## SUMMARY

Several overuse injuries can affect the upper extremity of tennis players. A thorough understanding of anatomy and knowledge of these common conditions and their treatment facilitates the management of these athletes.

## References

- Adelsberg S: The tennis stroke: An EMG analysis of selected muscles with rackets of increasing grip size. *Am J Sports Med* 14:139-142, 1986
- Andrews JR, Kupferman SP, Dillman CJ: Labral tears in throwing and racquet sports. *Clin Sports Med* 10:901-911, 1991
- Bell RH, Hawkins RJ: Stress fracture of the distal ulna: A case report. *Clin Orthop* 209:169-171, 1986
- Bigliani LU, Kimmel J, McCann PD, et al: Repair of rotator cuff tears in tennis players. *Am J Sports Med* 20:112-117, 1992
- Bigliani LU, Codd TP, Connor PM, et al: Shoulder motion and laxity in the professional baseball player. *Am J Sports Med* 25:609-613, 1997
- Bollen SR, Robinson DG, Crichton KJ, et al: Stress fractures of the ulna in tennis players using a double-handed backhand stroke. *Am J Sports Med* 21:751-752, 1993
- Boyer MI, Hastings H 2nd: Lateral tennis elbow: Is there any science out there? *J Shoulder Elbow Surg* 8:481-491, 1999
- Brown LP, Niehues SL, Harrah A, et al: Upper extremity range of motion and isokinetic strength of the internal and external shoulder rotators in major league baseball players. *Am J Sports Med* 16:577-585, 1988
- Burkhart SS: Os acromiale in a professional tennis player. *Am J Sports Med* 20:483-484, 1992
- Carter PR, Eaton RG, Littler JW: Ununited fracture of the hook of the hamate. *J Bone Joint Surg [Am]* 59:583-588, 1977
- Chandler TJ, Kibler WB, Stracener EC, et al: Shoulder strength, power, and endurance in college tennis players. *Am J Sports Med* 20:455-458, 1992
- Chow JW, Carlton LG, Lim YT, et al: Muscle activation during the tennis volley. *Med Sci Sports Exerc* 31:846-854, 1999
- Cohen DB, Mont MA, Campbell KR, et al: Upper extremity physical factors affecting tennis serve velocity. *Am J Sports Med* 22:746-750, 1994
- Cordasco FA, Parkes JC: Overuse injuries of the elbow. In Nicholas J, Hershman E (eds): *The Upper Extremity in Sports Medicine*. St. Louis, Mosby, 1995, pp 317-330
- Davidson PA, El'Attrache NS, Jobe CM, et al: Rotator cuff and postero-superior glenoid labrum injury associated with increased glenohumeral motion: A new site of impingement. *J Shoulder Elbow Surg* 4:384-390, 1994
- Drinkwater BL, Bruemner B, Chesnut CH: Menstrual history as a determinant of current bone density in young athletes. *JAMA* 263:545-548, 1990
- Drinkwater BL, Nilson K, Chesnut CH, et al: Bone mineral content of amenorrheic and eumenorrheic athletes. *N Engl J Med* 311:277-281, 1984
- Drinkwater BL, Nilson K, Ott S, et al: Bone mineral density after resumption of menses in amenorrheic athletes. *JAMA* 256:380-382, 1986
- Ellenbecker TS: Rehabilitation of shoulder and elbow injuries in tennis players. *Clin Sports Med* 14:87-110, 1995
- Ellenbecker TS, Roetert EP: Testing isokinetic muscular fatigue of shoulder internal and external rotation in elite junior tennis players. *J Orthop Sports Phys Ther* 29:275-281, 1999
- Ellenbecker TS, Roetert EP, Piorkowski PA, et al: Glenohumeral joint internal and external rotation range of motion in elite junior tennis players. *J Orthop Sports Phys Ther* 24:336-341, 1996
- Failla JM: Osteonecrosis associated with nonunion of the hook of the hamate. *Orthopedics* 16:217-218, 1993
- Field LD, Altchek DW: Elbow injuries. *Clin Sports Med* 14:59-78, 1995
- Friden J, Lieber RL: Physiologic consequences of surgical lengthening of extensor carpi radialis brevis muscle-tendon junction for tennis elbow. *J Hand Surg [Am]* 19:269-274, 1994
- Gerber C, Krushell RJ: Isolated rupture of the tendon of the subscapularis muscle. Clinical features in 16 cases. *J Bone Joint Surg Br* 73:389-394, 1991
- Giagarra CE, Conroy B, Jobe FW, et al: Electromyographic and cinematographic analysis of elbow function in tennis players using single- and double-handed backhand strokes. *Am J Sports Med* 21:394-399, 1993
- Gregg JR, Torg E: Upper extremity injuries in adolescent tennis players. *Clin Sports Med* 7:371-385, 1988
- Gunn CC, Milbrandt WE: Tennis elbow and the cervical spine. *Can Med Assoc J* 114:803-809, 1976
- Hageman CE, Lehman RC: Stretching, strengthening, and conditioning for the competitive tennis player. *Clin Sports Med* 7:211-228, 1988
- Haker E, Lundeberg T: Acupuncture treatment in epicondylalgia: A comparative study of two acupuncture techniques. *Clin J Pain* 6:221-226, 1990
- Haker E, Lundeberg T: Laser treatment applied to acupuncture points in lateral humeral epicondylalgia: A double-blind study. *Pain* 43:243-247, 1990
- Haker E, Lundeberg T: Pulsed ultrasound treatment in lateral epicondylalgia. *Scand J Rehabil Med* 23:115-118, 1991
- Haker EH, Lundeberg TC: Lateral epicondylalgia: Report of noneffective midlaser treatment. *Arch Phys Med Rehabil* 72:984-988, 1991
- Hartyman DT, Sidles JA, Clark JM, et al: Translation of the humeral head on the glenoid with passive glenohumeral motion. *J Bone Joint Surg [Am]* 72:1334-1343, 1990
- Hawkins RJ, Kennedy JC: Impingement syndrome in athletes. *Am J Sports Med* 8:151-158, 1980
- Hecht P, Hayashi K, Cooley AJ, et al: The thermal effect of monopolar radiofrequency energy on the properties of joint capsule: An in vivo histologic study using a sheep model. *Am J Sports Med* 26:808-814, 1998
- Hennig EM, Rosenbaum D, Milani TL: Transfer of tennis racket vibrations onto the human forearm. *Med Sci Sports Exerc* 24:1134-1140, 1992
- Huddleston AL, Rockwell D, Kulund DN, et al: Bone mass in lifetime tennis athletes. *JAMA* 244:1107-1109, 1980
- Ilfeld FW: Can stroke modification relieve tennis elbow? *Clin Orthop* 276:182-186, 1992
- Jobe CM, Sidles L: Evidence for a superior glenoid impingement upon the rotator cuff. *J Shoulder Elbow Surg* 2:S19, 1993
- Kännus P, Haapasalo H, Sievanen H, et al: The site-specific effects of long-term unilateral activity on bone mineral density and content. *Bone* 15:279-284, 1994
- Kibler WB: Clinical biomechanics of the elbow in tennis: implications for evaluation and diagnosis. *Med Sci Sports Exerc* 26:1203-1206, 1994
- Kibler WB: Biomechanical analysis of the shoulder during tennis activities. *Clin Sports Med* 14:79-85, 1995
- Kibler WB, Chandler TJ, Livingston BP, et al: Shoulder range of motion in elite tennis players: Effect of age and years of tournament play. *Am J Sports Med* 24:279-285, 1996
- Koplan JP, Siscovick DS, Goldbaum GM: The risks of exercise: A public health view of injuries and hazards. *Public Health Rep* 100:189-195, 1985
- Kuhn JE, Hawkins RJ: Surgical treatment of shoulder injuries in tennis players. *Clin Sports Med* 14:139-161, 1995
- Kuklo TR, Taylor KE, Murphy KP, et al: Arthroscopic release for lateral epicondylitis: A cadaveric model. *Arthroscopy* 15:259-264, 1999
- Kulund DN, McCue FC 3rd, Rockwell DA, et al: Tennis injuries: Prevention and treatment. A review. *Am J Sports Med* 7:249-253, 1979
- Le Huec JC, Schaefferbeke T, Chauveaux D, et al: Epicondylitis after treatment with fluoroquinolone antibiotics. *J Bone Joint Surg Br* 77:293-295, 1995

50. Leach RE, Abramowitz A: The senior tennis player. *Clin Sports Med* 10:283-290, 1991
51. Lee HW: Mechanisms of neck and shoulder injuries in tennis players. *J Orthop Sports Phys Ther* 21:28-37, 1995
52. Lehman RC: Shoulder pain in the competitive tennis player. *Clin Sports Med* 7:309-327, 1988
53. Lehman RC: Surface and equipment variables in tennis injuries. *Clin Sports Med* 7:229-232, 1988
54. Loosli AR, Leslie M: Stress fractures of the distal radius: A case report. *Am J Sports Med* 19:523-524, 1991
55. Lopez MJ, Hayashi K, Fanton GS, et al: The effect of radiofrequency energy on the ultrastructure of joint capsular collagen. *Arthroscopy* 14: 495-501, 1998
56. Maylack FH: Epidemiology of tennis, squash, and racquetball injuries. *Clin Sports Med* 7:233-243, 1988
57. McCann PD, Bigliani LU: Shoulder pain in tennis players. *Sports Med* 17:53-64, 1994
58. Meister K, Andrews JR: Classification and treatment of rotator cuff injuries in the overhand athlete. *J Orthop Sports Phys Ther* 18:413-421, 1993
59. Mont MA, Cohen DB, Campbell KR, et al: Isokinetic concentric versus eccentric training of shoulder rotators with functional evaluation of performance enhancement in elite tennis players. *Am J Sports Med* 22:513-517, 1994
60. Morris M, Jobe FW, Perry J, et al: Electromyographic analysis of elbow function in tennis players. *Am J Sports Med* 17:241-247, 1989
61. Murakami Y: Stress fracture of the metacarpal in a adolescent tennis player. *Am J Sports Med* 16:419-420, 1988
62. Naseef GS 3rd, Foster TE, Trauner K, et al: The thermal properties of bovine joint capsule: the basic science of laser- and radiofrequency-induced capsular shrinkage. *Am J Sports Med* 25:670-674, 1997
63. Neer CS 2nd: Impingement lesions. *Clin Orthop* 173:70-77, 1983
64. Neviasser RJ: Lesions of the biceps and tendinitis of the shoulder. *Orthop Clin North Am* 11:343-348, 1980
65. Nirschl RP: Soft-tissue injuries about the elbow. *Clin Sports Med* 5:637-652, 1986
66. Nirschl RP: Prevention and treatment of elbow and shoulder injuries in the tennis player. *Clin Sports Med* 7:289-308, 1988
67. Nirschl RP: Elbow tendinosis/tennis elbow. *Clin Sports Med* 11:851-870, 1992
68. O'Brien SJ, Pagnani MJ, Fealy S, et al: The active compression test: A new and effective test for diagnosing labral tears and acromioclavicular joint abnormality. *Am J Sports Med* 26:610-613, 1998
69. Obrzut SL, Hecht P, Hayashi K, et al: The effect of radiofrequency energy on the length and temperature properties of the glenohumeral joint capsule. *Arthroscopy* 14:395-400, 1998
70. Ollivierre CO, Nirschl RP: Tennis elbow: Current concepts of treatment and rehabilitation. *Sports Med* 22:133-139, 1996
71. Osterman AL: Arthroscopic debridement of triangular fibrocartilage complex tears. *Arthroscopy* 6:120-124, 1990
72. Osterman AL, Moskow L, Low DW: Soft-tissue injuries of the hand and wrist in racquet sports. *Clin Sports Med* 7:329-348, 1988
73. Osterman AL, Terrill RG: Arthroscopic treatment of TFCC lesions. *Hand Clin* 7:277-281, 1991
74. Perry J: Anatomy and biomechanics of the shoulder in throwing, swimming, gymnastics, and tennis. *Clin Sports Med* 2:247-270, 1983
75. Plancher KD, Litchfield R, Hawkins RJ: Rehabilitation of the shoulder in tennis players. *Clin Sports Med* 14:111-137, 1995
76. Posch JN, Goldberg VM, Larrey R: Extensor fasciotomy for tennis elbow: A long-term follow-up study. *Clin Orthop* 135:179-182, 1978
77. Posner MA: Injuries to the hand and wrist in athletes. *Orthop Clin North Am* 8:593-618, 1977
78. Potter HG, Hannafin JA, Morwessel RM, et al: Lateral epicondylitis: correlation of MR imaging, surgical, and histopathologic findings. *Radiology* 196:43-46, 1995
79. Price R, Sinclair H, Heinrich I, et al: Local injection treatment of tennis elbow—hydrocortisone, triamcinolone and lignocaine compared. *Br J Rheumatol* 30:39-44, 1991
80. Priest JD: The shoulder of the tennis player. *Clin Sports Med* 7:387-402, 1988
81. Priest JD, Nagel DA: Tennis shoulder. *Am J Sports Med* 4:28-42, 1976
82. Prochaska V, Crosby LA, Murphy RP: High radial nerve palsy in a tennis player. *Orthop Rev* 22:90-92, 1993
83. Rayan GM: Recurrent dislocation of the extensor carpi ulnaris in athletes. *Am J Sports Med* 11:183-184, 1983
84. Rettig AC: Stress fracture of the ulna in an adolescent tournament tennis player. *Am J Sports Med* 11:103-106, 1983
85. Rettig AC: Wrist problems in the tennis player. *Med Sci Sports Exerc* 26:1207-1212, 1994
86. Rettig AC, Beltz HF: Stress fracture in the humerus in an adolescent tennis tournament player. *Am J Sports Med* 13:55-58, 1985
87. Rettig ME, Dassa GL, Raskin KB, et al: Wrist fractures in the athlete: Distal radius and carpal fractures. *Clin Sports Med* 17:469-489, 1998
88. Richardson AB: Overuse syndromes in baseball, tennis, gymnastics, and swimming. *Clin Sports Med* 2:379-390, 1983
89. Rompe JD, Hopf C, Kullmer K, et al: Low-energy extracorporeal shock wave therapy for persistent tennis elbow. *Int Orthop* 20:23-27, 1996
90. Rowe CR, Zarins B: Recurrent transient subluxation of the shoulder. *J Bone Joint Surg [Am]* 63:863-872, 1981
91. Rupp S, Seil R, Kohn DM: Surgical reconstruction of a stress fracture of the acromion after arthroscopic subacromial decompression in an elite tennis player. *Arthroscopy* 14:106-108, 1998
92. Ryu RK, McCormick J, Jobe FW, et al: An electromyographic analysis of shoulder function in tennis players. *Am J Sports Med* 16:481-485, 1988
93. Schultz JS, Leonard JA Jr: Long thoracic neuropathy from athletic activity. *Arch Phys Med Rehabil* 73:87-90, 1992
94. Stark HH, Jobe FW, Boyes JH, et al: Fracture of the hook of the hamate in athletes. *J Bone Joint Surg [Am]* 59:575-582, 1977
95. Townsend H, Jobe FW, Pink M, Perry J: Electromyographic analysis of the glenohumeral muscles during a baseball rehabilitation program. *Am J Sports Med* 19:264-272, 1991
96. Verhaar J, Walenkamp G, Kester A, et al: Lateral extensor release for tennis elbow. A prospective long-term follow-up study. *J Bone Joint Surg [Am]* 75:1034-1043, 1993
97. Walch G, Boileau P, Noel E, et al: Impingement of the deep surface of the supraspinatus tendon on the posterosuperior glenoid rim: an arthroscopic study. *J Shoulder Elbow Surg* 1:238-245, 1992
98. Wall MS, Deng XH, Torzilli PA, et al: Thermal modification of collagen. *J Shoulder Elbow Surg* 8:339-344, 1999
99. Waninger KN, Lombardo JA: Stress fracture of index metacarpal in an adolescent tennis player. *Clin J Sport Med* 5:63-66, 1995
100. Yergason RM: Supination sign. *J Bone Joint Surg* 13:160, 1931
101. Young CC, Raasch WG, Geiser C: Ulnar stress fracture of the nondominant arm in a tennis player using a two-handed backhand. *Clin J Sport Med* 5:262-264, 1995

Address reprint requests to  
Frank A. Cordasco, MD  
Sports Medicine and Shoulder Service  
Hospital for Special Surgery  
535 East 70th Street  
New York, NY 10021