

# Small Medial Meniscocapsular Separations: A Potential Cause of Chronic Medial-Side Knee Pain

Iftach Hetsroni, M.D., Kaitlyn Lillemoe, B.A., and Robert G. Marx, M.D., M.Sc., F.R.C.S.C.

---

**Purpose:** To describe clinical characteristics, surgical findings, and functional outcome after arthroscopic repair of a unique type of meniscocapsular separation. **Methods:** We retrospectively reviewed office charts, magnetic resonance imaging (MRI) scans, operative reports, and arthroscopic images of 6 patients who underwent surgery between January 2007 and May 2009, in whom a medial meniscocapsular separation measuring less than 5 mm in length was identified and treated. Inclusion criteria were medial-side knee pain unresponsive to nonoperative management, negative MRI findings, and an isolated meniscocapsular separation injury detected on arthroscopy and repaired with 1 stitch. Patients were contacted and completed questionnaires that included subjective International Knee Documentation Committee, Tegner, and Marx scores. **Results:** Of the 6 patients, 5 were female patients aged 14 to 18 years who were involved in sports. All patients recalled an acute twisting knee injury. Symptoms were related mainly to sports and were absent or very minimal during activities of daily living. On physical examination, the medial joint line was tender in all patients, whereas medial-side knee discomfort while squatting (i.e., baseball catcher's position) and McMurray tests were positive only in some. The negative MRI scans used a 3-T magnet in 5 cases and a 1.5-T magnet in 1 case. The duration of symptoms from injury to surgery was between 6 months and 9 years in 5 cases. On arthroscopy, all patients had a medial meniscocapsular separation measuring less than 5 mm in length that was identified when the tip of the arthroscopic probe was inserted into the lesion. This was repaired with a single all-inside stitch. The mean latest follow-up was 31 months (range, 15 to 38 months). The mean subjective International Knee Documentation Committee score was 87 at latest follow-up. Tegner and Marx scores showed that after surgery, 5 patients regained their preinjury level of activity. **Conclusions:** Meniscocapsular separation can involve a segment of less than 5 mm in length, be occult on MRI, be challenging to visualize on arthroscopy, and lead to chronic medial-side knee pain. Critical evaluation with a history, physical examination, and careful arthroscopic inspection of the medial meniscus can lead to appropriate treatment with a good to excellent outcome after repair. **Level of Evidence:** Level IV, therapeutic case series.

---

---

*From the Department of Orthopedic Surgery, Meir General Hospital, Sapir Medical Center (I.H.), Kfar Saba, Israel; Sackler Faculty of Medicine, Tel Aviv University (I.H.), Tel Aviv, Israel; and Hospital for Special Surgery, Weill Medical College of Cornell University (K.L., R.G.M.), New York, New York, U.S.A.*

*The authors report no conflict of interest.*

*Received September 13, 2010; accepted June 17, 2011.*

*Address correspondence to Robert G. Marx, M.D., M.Sc., F.R.C.S.C., Hospital for Special Surgery, Weill Medical College of Cornell University, 535 E 70th St, New York, NY 10021, U.S.A. E-mail: marxr@hss.edu*

*© 2011 by the Arthroscopy Association of North America  
0749-8063/10543/\$36.00*

*doi:10.1016/j.arthro.2011.06.025*

Meniscocapsular separation is an uncommon injury.<sup>1</sup> It is typically accompanied by ligament tears (anterior cruciate ligament [ACL], posterior cruciate ligament, medial collateral ligament).<sup>1-4</sup> The injured area usually involves over 1 cm of disrupted meniscocapsular tissue, requiring several sutures for repair.<sup>2,4</sup>

In this study we describe a series of patients who presented with longstanding medial-side knee pain that followed low-energy knee trauma and did not respond to nonoperative management. Magnetic resonance imaging (MRI) scans, which used a 3-T magnet in 5 cases and a 1.5-T magnet in 1 case, a sagittal and coronal slice width of 3.5 mm, and no intersection

gap, were negative in all cases. During arthroscopy, there was a detachment of less than 5 mm in length (measured with the right angle tip of the arthroscopic probe used as a scale) at the capsular attachment of the medial meniscus posterior horn or posterior horn–body junction area. The injury was identified by inserting the tip of the arthroscopic probe into the lesion showing meniscal instability. Contrary to previously described meniscocapsular separations, no other significant intra-articular abnormalities or ligament disruptions accompanied the injury. The purpose of this study is to describe clinical characteristics and surgical findings of this pathology, as well as to report functional outcome after arthroscopic repair. We hypothesized that a good to excellent outcome is achieved after repair of this type of meniscocapsular separation.

## METHODS

This study includes 6 consecutive patients who underwent surgery by the senior author (R.G.M.) at a single institution between January 2007 and May 2009. Office charts, MRI scans, operative reports, and arthroscopic images were reviewed. Inclusion criteria were medial-side knee pain unresponsive to nonoperative management (i.e., activity modification and physical therapy), physical examination findings indicating tenderness on palpation of the medial joint line, negative MRI findings, and an isolated meniscocapsular separation injury detected on arthroscopy and repaired with only 1 stitch. In 5 patients the magnetic resonance (MR) magnet was 3 T and in 1 case it was

1.5 T. Sequences included fast spin-echo sagittal, axial, and coronal images, as well as inversion recovery sagittal sequence images, performed with and without fat suppression. Sagittal as well as coronal slice width was 3.5 mm with no intersection gap between slices. The repair technique included debridement of the meniscocapsular damaged tissue with a 4.5 mm full-radius shaver, followed by a single all-inside No. 2-0 nonabsorbable suture in a horizontal-oblique configuration. The intercondylar notch, just anterior to the ACL, was then debrided with the shaver, causing some bleeding to potentially promote healing of the repair. The postoperative protocol included 3 weeks of non-weight bearing and knee motion in a brace limited to 0° to 90° until 6 weeks. After 3 weeks, full weight bearing was allowed. After 6 weeks, full motion was allowed, except squatting. Running was allowed at 4 months and squatting with unrestricted activities at 6 months. Patients were contacted and completed functional questionnaires that included subjective International Knee Documentation Committee score, Tegner activity level score, and Marx activity level score. Descriptive statistics included individual as well as mean values for the functional scores. The study was approved by our institutional review board, and all participants signed informed consent forms.

## RESULTS

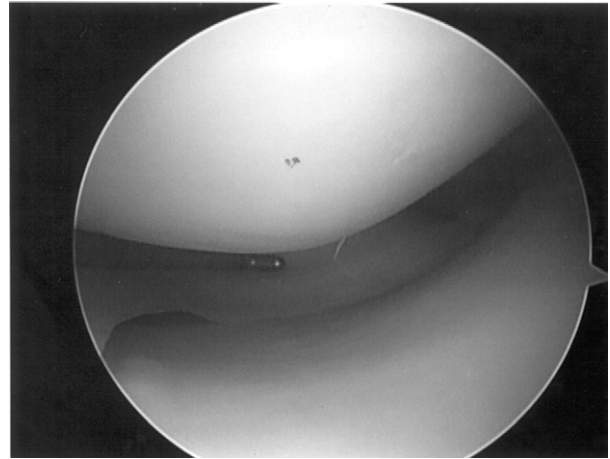
Table 1 presents patient demographics, injury characteristics, and surgical findings. Of the 6 patients, 5 were female aged 14 to 18 years who were involved in

**TABLE 1.** Patient Demographics, Injury Characteristics, and Surgical Findings

| Case No. | Age (yr) | Sex | Injury Mechanism                      | Symptom-Related Activity                | MRI Magnet and Interpretation                      | Symptoms Duration From Injury to Surgery | Area of Medial Meniscocapsular Separation and Procedure |
|----------|----------|-----|---------------------------------------|---|--|--|---|
| 1        | 17       | F   | Twisting and pivoting during soccer   | Twisting and pivoting during soccer     | 3 T, normal findings                               | 3 mo                                     | Posterior horn–body junction, 1 all-inside stitch       |
| 2        | 14       | F   | Twisting and pivoting during soccer   | Running                                 | 3 T, normal findings                               | 2 yr                                     | Posterior horn, 1 all-inside stitch                     |
| 3        | 17       | F   | Twisting and pivoting during lacrosse | Long walks, running, twisting, pivoting | 1.5 T, mild knee effusion, patellar tendinosis     | 1 yr                                     | Posterior horn–body junction, 1 all-inside stitch       |
| 4        | 15       | F   | Jump landing during gymnastics        | Jumping                                 | 3 T, normal findings                               | 3 yr                                     | Posterior horn, 1 all-inside stitch                     |
| 5        | 18       | F   | Twisting during figure skating        | Long walks, stairs, twisting            | 3 T, normal findings                               | 6 mo                                     | Posterior horn, 1 all-inside stitch                     |
| 6        | 48       | M   | Jump landing                          | Long walks, jogging, running            | 3 T, mild knee effusion, otherwise normal findings | 9 yr                                     | Posterior horn–body junction, 1 all-inside stitch       |

sports. All patients could recall an acute injury initiating their symptoms, which involved knee twisting during sports activity or landing from a jump. Symptoms were related mainly to sports and were absent or very minimal during activities of daily living. Physical examination in all patients showed tenderness on palpation of the medial joint line. Other provocative meniscal tests showed uncomfortable squatting (i.e., the position of a baseball catcher) in 5 of the 6 patients and a positive McMurray test in 4 patients. Knee examination was otherwise normal in all cases (i.e., ligament stability maintained and no effusion). The MRI scans did not show any meniscus or meniscocapsular injury pattern (Fig 1). The duration of symptoms from injury to surgery was between 6 months and 9 years in 5 cases. For 1 patient (case 1), the decision was made to proceed with surgery after only 3 months because the patient was unable to run and she wanted to return to competitive soccer for the upcoming season. During arthroscopy, all patients had a small medial meniscocapsular separation that was repaired with a single all-inside stitch. Before being operated on at our institution, 1 patient (case 3) had a history of negative arthroscopy findings with persis-

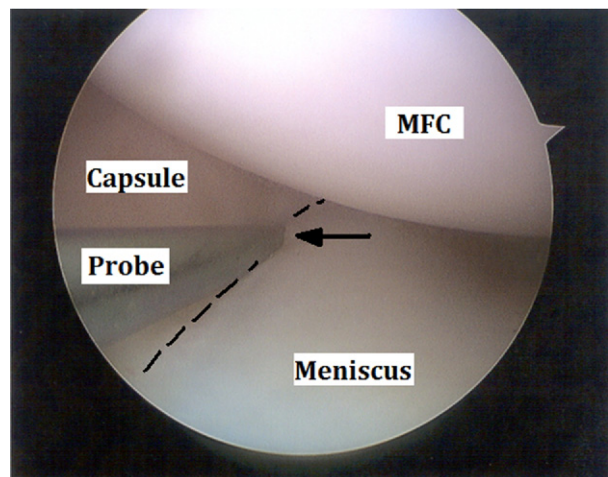
**FIGURE 1.** A 3-T MRI sagittal slice of a right knee not showing abnormality at the medial meniscus posterior horn–body junction area of a patient, where a small meniscocapsular separation was found later during arthroscopy. The inset shows a coronal view, indicating the location of the sagittal slice (white line), which corresponds to the posterior horn–body junction area of the medial meniscus.



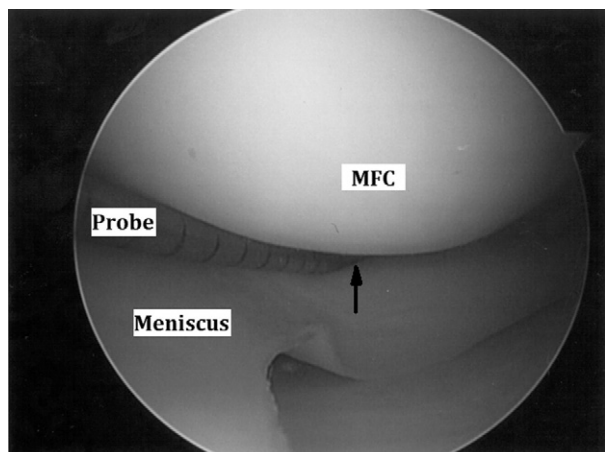
**FIGURE 2.** Normal-appearing medial meniscus viewed from anterior-lateral portal.

tent symptoms. In this case the symptoms resolved after repair of the small meniscocapsular separation.

Figures 2 through 5 show the arthroscopic findings. This included a normal-appearing medial meniscus viewed from the anterior-lateral portal (Fig 2). When the lesion involved the posterior horn–body junction area, it could be clearly seen when the tip of the probe was inserted into the defect (Fig 3). In cases involving the posterior horn, the lesion was identified when the tip of the probe was inserted above and beyond the highest peripheral rim of the meniscus into the lesion, and the meniscus was then pulled slightly underneath



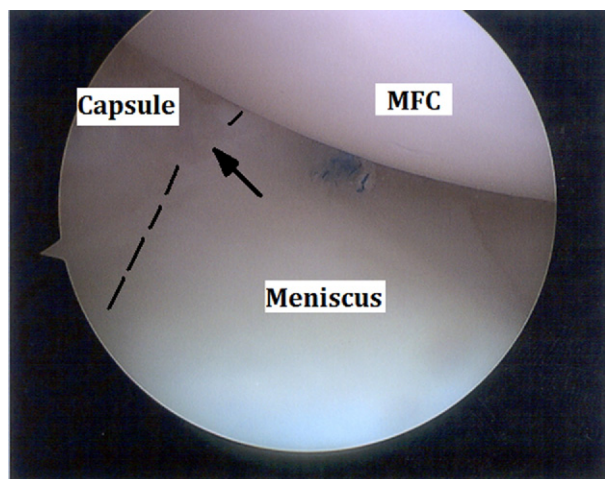
**FIGURE 3.** A lesion involving the posterior horn–body junction area is clearly seen when the tip of the probe is inserted into the defect. The arrow points to the lesion. The dashed line overlies the meniscocapsular junction. (MFC, medial femoral condyle.)



**FIGURE 4.** A lesion (arrow) involving the posterior horn is identified when the tip of the probe is inserted above and beyond the highest peripheral rim of the meniscus into the lesion. The meniscus is pulled underneath the medial femoral condyle (MFC), showing instability of the meniscus.

the medial femoral condyle, showing instability of the meniscus (Fig 4). This instability could be shown when the probe was inserted into the lesion from underneath the meniscus as well. The lesion was repaired with 1 all-inside No. 2-0 suture (Fig 5).

At the routine 6-month follow-up visit, medial joint line tenderness resolved in all patients. The mean latest follow-up was 31 months (Table 2). Five patients had a minimum of 24 months' follow-up. The mean subjective International Knee Documentation



**FIGURE 5.** The lesion is repaired with 1 all-inside suture. The arrow points to the meniscocapsular lesion area after it is repaired. The dashed line overlies the meniscocapsular junction. (MFC, medial femoral condyle.)

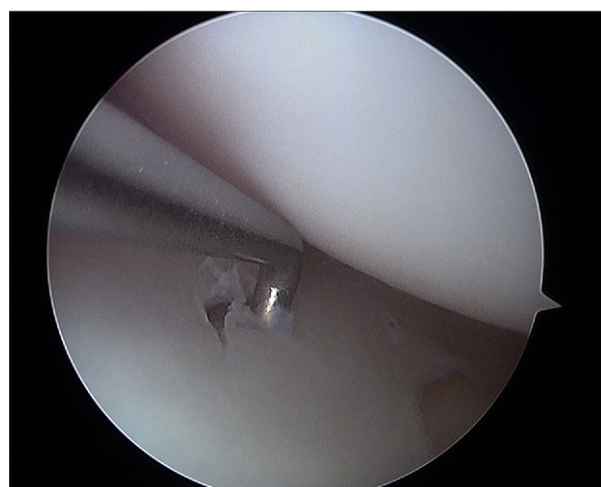
**TABLE 2.** Functional Scores

| Case No. | Latest Follow-up (mo) | Subjective IKDC Score at Latest Follow-up | Tegner Score (BI, BIS, C) | Marx Score (BI, BIS, C) |
|----------|-----------------------|---|---------------------------|-------------------------|
| 1        | 38                    | 99  | 9, 7, 7                   | 16, 8, 16               |
| 2        | 38                    | *   | 9, *, 9                   | 16, *, 16               |
| 3        | 15                    | 72  | 9, 2, 6                   | 16, 0, 3                |
| 4        | 35                    | 87  | 9, 7, 9                   | 12, 8, 12               |
| 5        | 24                    | 93  | 9, 2, 7                   | 12, 4, 11               |
| 6        | 36                    | 85  | 4, 4, 4                   | 8, 4, 8                 |
| Mean     | 31                    | 87  | 8, 4, 7                   | 13, 5, 11               |

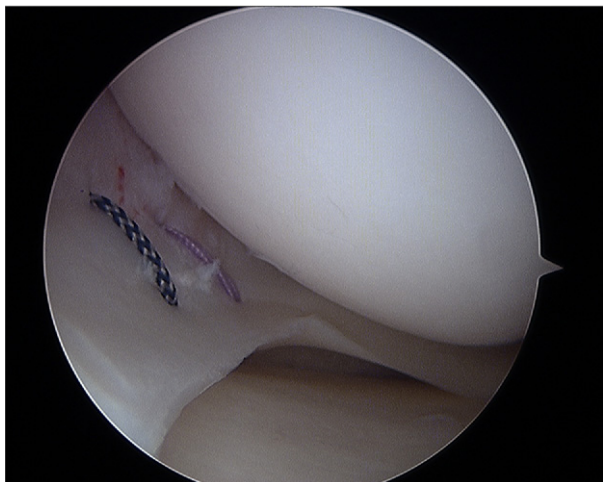
Abbreviations: IKDC, International Knee Documentation Committee; BI, before injury; BIS, between injury and surgery; C, current (at latest follow-up).

\*Information unavailable (incomplete patient compliance).

Committee score was 87 at latest follow-up. The Tegner and Marx scores showed that after surgery, 5 patients regained their preinjury level of activity completely or almost completely. These patients also reported specifically that their medial pain resolved during sports activity. Four of these involved high-level competitive sports. In 1 patient, a 17-year-old girl (case 3), symptoms resolved after surgery, and she returned to full activity. However, at 15 months after surgery, her medial pain gradually recurred. We therefore suspected failure of the repair, and she was scheduled to undergo revision arthroscopy. On revision, it was apparent that the suture had pulled through the meniscus, leading to a larger tear (Fig 6). A revision



**FIGURE 6.** Revision arthroscopy image showing a meniscus tear caused by the primary meniscocapsular repair suture, which had pulled through the meniscus.



**FIGURE 7.** Revision vertical outside-in repair was carried out by use of 2 sutures.

repair was carried out with a vertical outside-in repair using 2 sutures (Fig 7).

## DISCUSSION

Meniscocapsular separation is a rare injury that is typically accompanied by ligament tears.<sup>1-4</sup> The separation usually involves more than 1 cm in length and requires several stitches for repair.<sup>2,4</sup> The lesions described in this study may therefore represent a unique subgroup of meniscocapsular separations because this injury was an isolated injury, involved not more than 5 mm in length, was occult on MRI and hard to visualize on arthroscopy, and required only 1 stitch for repair.

The data provided show that patients presenting with this injury share several characteristics. These relate to patient demographics, mechanism of injury, and symptom characteristics, as well as surgical findings.

Of the 6 patients, 5 were female teenagers involved in cutting and pivoting sports, and all 6 patients could recall a specific noncontact knee injury that initiated the symptoms. We cannot explain the reason for young female predominance. Theoretically, this may be related to the soft-tissue characteristics of the capsular attachment or to specific anthropometric characteristics of bone morphology and joint congruency, as well as sex-specific joint kinematics that may put the posterior medial meniscocapsular tissue under tensile stresses specifically in female patients. It has been shown that female patients have a poorer jump-landing tech-

nique than male patients, characterized by less knee and hip flexion, more knee valgus moment and hip internal rotation motion, and greater knee joint loading.<sup>5</sup> Although this may contribute to the increased risk of ACL injuries in female patients, in theory, such lower limb mechanics may contribute to subtle medial-side knee injuries as well. The injury at the meniscocapsular area may be an example of this, which could occur during a lower magnitude of forces compared with those required to result in an ACL injury. From a practical clinical standpoint, this observation may raise the index of suspicion for this injury in this specific age group of female patients when medial-side knee pain after a twisting knee injury fails to respond to nonoperative treatment.

In 4 cases the duration of symptoms was between 1 and 9 years from injury to surgery. Although all patients were clearly symptomatic during sports because of medial-side knee pain, their overall favorable function in daily activities permitted them to continue with nonoperative management for a prolonged duration. This could be related to 2 major factors in our opinion. First, because the separation was of small magnitude, we believe high loads (encountered during activities such as cutting or jumping) are required to cause meniscal displacement at the richly innervated capsule and therefore pain at the site of injury. Thus, activities of daily living that involve walking may not cause sufficient tension to displace the meniscus and stress the capsule to cause pain. Second, because the periphery of the meniscus is vascularized, some healing, though not optimal, may have taken place in some of these cases. In such a scenario, the partially healed meniscocapsular area may support activities of daily living but may not have been able to support higher stresses as encountered during sports.

The physical examination findings in all 6 cases showed at least 1 positive sign suggestive of a meniscus or meniscocapsular injury. Whereas McMurray tests and medial pain during full flexion were not positive in all cases, the medial joint line was always tender to palpation. This emphasizes the importance of medial joint line palpation specifically in this type of injury, because other common tests may not be sensitive enough.

The MRI findings, despite use of a 3-T magnet in 5 of 6 patients, were negative for meniscus or meniscocapsular injury. Several subtle diagnostic criteria and pitfalls on MRI have previously been described to help in the diagnosis of injuries to the meniscocapsular area. These included meniscal displacement, peripheral meniscal corner tears, increased perimeniscal

signal intensity, and fluid deep to the medial collateral ligament.<sup>6</sup> However, even when Rubin et al.<sup>1</sup> evaluated MR images prospectively and retrospectively in relation to knee arthroscopy to evaluate the accuracy of MRI to diagnose meniscocapsular injuries, looking for the previously mentioned specific signs, the positive predictive value of the MRI was less than 10%. It is not surprising therefore that the small lesion described in our patients was not detected on MRI. We thus agree that because of the size of the lesion, it may have been missed on the MRI scans. Another potential explanation for the negative MRI findings may be related to the fact that MRI is performed with the patient lying supine, and therefore, with no body weight applied to the meniscus, it may not be displaced (these lesions were asymptomatic during everyday activities as we described), concealing its existence.

MR arthrography is another option that could increase the sensitivity of intra-articular pathology diagnosis. However, it has been shown that although this MR modality may theoretically document interposition of contrast media between the meniscus and the medial collateral ligament, practically, this finding was present in the minority of knees with meniscocapsular separations, putting into question the usefulness of this diagnostic tool.<sup>7</sup> In addition, if significant edema or fibrosis is present in the area of the meniscocapsular injury, contrast material may not locate in this area.<sup>7</sup> We proceeded with surgery in our patients despite the negative imaging in view of the duration of symptoms and limitation in function. It was decided that the potential benefits from arthroscopic intervention outweighed the risk of negative arthroscopy finding.

Arthroscopy should always follow an orderly examination with probing all knee compartments to avoid overlooking a subtle injury. The cases presented show how important this probing is, specifically in the medial meniscocapsular area. The meniscocapsular lesions presented in this study were not obvious by viewing with the 30° arthroscope from the anterior-lateral portal. Adhering to principles as previously described,<sup>8</sup> as well as careful probing of the meniscocapsular area from above and underneath the medial meniscus allowed identification of the lesion. This is of specific interest in 1 of our cases in which a previous arthroscopy had been performed at another institution after the initial injury but did not identify the separation. Because symptoms persisted after that procedure despite a long period of rehabilitation, we repeated the arthroscopy and repaired the lesion. This case emphasizes the importance of being aware of this

injury and the careful critical probing of the meniscocapsular area.

The functional scores in 5 of 6 patients support our hypothesis, showing that a good to excellent outcome with return to preinjury level of activity is achieved after repair of the lesion. This is likely related to the rich vascularity of the periphery of the meniscus, which provides excellent healing potential in this area.

Long-standing medial-side knee pain after noncontact knee injury should not be routinely diagnosed as meniscus or meniscocapsular lesion. Other sources of discomfort in this area include medial collateral ligament injuries, articular cartilage injuries, bone bruise, patellofemoral pain, and radicular symptoms from either the hip joint or the lower lumbar spine. Before any arthroscopic procedure is performed to address a suspected meniscus pathology or meniscocapsular lesion, care must therefore be applied to rule out these and other sources of pain that may respond to a nonoperative approach. At the same time, clinical suspicion should be applied to possible uncommon lesions when history and physical examination support an intra-articular source for symptoms. An extensive period of nonoperative treatment and watchful waiting are therefore appropriate before considering arthroscopy.

Weaknesses of this study include the small number of cases, as well as the retrospective nature of the study, which makes it impossible to estimate accurately the prevalence of this injury in the population.

## CONCLUSIONS

Meniscocapsular separation can involve a segment of less than 5 mm in length, be occult on MRI, be challenging to visualize on arthroscopy, and lead to chronic medial-side knee pain. Critical evaluation with a history, physical examination, and careful arthroscopic inspection of the medial meniscus can lead to appropriate treatment with a good to excellent outcome after repair.

## REFERENCES

1. Rubin DA, Britton CA, Towers JD, Harner CD. Are MR imaging signs of meniscocapsular separation valid? *Radiology* 1996;201:829-836.
2. Hamberg P, Gillquist J, Lysholm J. Suture of new and old peripheral meniscus tears. *J Bone Joint Surg Am* 1983;65:193-197.
3. Potter HG, Weinstein M, Allen AA, Wickiewicz TL, Helfet DL. Magnetic resonance imaging of the multiple-ligament injured knee. *J Orthop Trauma* 2002;16:330-339.

4. Strand T, Engesaeter LB, Mølster AO. Meniscus repair in knee ligament injuries. *Acta Orthop Scand* 1985;56:130-132.
5. Padua DA, Marshall SW, Boling MC, Thigpen CA, Garrett WE Jr, Beutler AI. The Landing Error Scoring System (LESS) is a valid and reliable clinical assessment tool of jump-landing biomechanics: The JUMP-ACL study. *Am J Sports Med* 2009;37:1996-2002.
6. De Maeseneer M, Shahabpour M, Vanderdood K, Van Roy F, Osteaux M. Medial meniscocapsular separation: MR imaging criteria and diagnostic pitfalls. *Eur J Radiol* 2002;41:242-252.
7. De Maeseneer M, Lenchik L, Starok M, Pedowitz R, Trudell D, Resnick D. Normal and abnormal medial meniscocapsular structures: MR imaging and sonography in cadavers. *AJR Am J Roentgenol* 1998;171:969-976.
8. Carson WG Jr. Arthroscopic techniques to improve access to posterior meniscal lesions. *Clin Sports Med* 1990;9:619-632.

**ABSTRACTS IN SPANISH!**

**¡RESÚMENES AL ESPAÑOL!**

**are now available at [www.arthroscopyjournal.org](http://www.arthroscopyjournal.org)**

**Subscribers can access from the Table of Contents by clicking "Supplemental Materials." Nonsubscribers can access the Spanish Abstracts by issue for free from the home page.**