

## Osteoarthritis Following Shoulder Instability

Robert H. Brophy, MD, MS<sup>a,\*</sup>, Robert G. Marx, MD<sup>a,b</sup>

<sup>a</sup>*Hospital for Special Surgery, 535 East 70<sup>th</sup> Street, New York, NY 10021, USA*

<sup>b</sup>*Weill Medical College of Cornell University, 525 East 68th Street, New York, NY 10021, USA*

Although dislocation of the shoulder is a common injury, estimated to occur in 0.5% to 1.7% [1,2] of individuals, the association between shoulder dislocation and the development of glenohumeral arthrosis has not been well studied or established in the literature. Rowe and others have discussed complications arising from shoulder dislocations; however, there was no mention of degenerative arthritis of the glenohumeral joint [3,4]. Considering the association between dislocation or recurrent instability and degenerative changes in other joints [5], it would appear reasonable to expect a similar relationship in the shoulder, especially considering the damage to cartilage and bone seen after traumatic shoulder dislocation [6].

Neer first recognized that a subset of patients with degenerative arthritis in the shoulder had a prior history of surgical repair for instability [7]. Samilson and Prieto [8] formally described the condition they called dislocation arthropathy of the shoulder, and noted such a finding even in patients with a single dislocation and no surgical intervention. Although there has been further research in this area, the understanding of this relationship is still evolving.

### Incidence

The incidence of shoulder arthropathy in patients with shoulder instability is difficult to measure. Given that the majority of shoulder dislocations occur in

---

\* Corresponding author.

*E-mail address:* brophyr@hss.edu (R.H. Brophy).

younger patients [9], following such a population until the onset of degenerative arthritis is not feasible. Moreover, the long time period between dislocation and arthritis makes it difficult to control for other events in the interim. Adding to the complexity is the high rate of recurrence seen with shoulder dislocation, ranging from 10% to 90% after an initial dislocation [6,10–15].

There is no doubt that the humeral head suffers cartilage damage with shoulder dislocation. Taylor and Arciero [6] reported a series of 63 patients with first-time traumatic dislocations who were evaluated arthroscopically within 10 days of their dislocation. Osteochondral lesions of the humeral head were noted in 34 patients and chondral lesions were noted in an additional 23. Norlin [16] reported a series of 24 patients with first-time anterior shoulder dislocation assessed arthroscopically 1 to 3 days after injury. Osteochondral lesions were found in six shoulders, and the remaining 18 were all noted to have chondral lesions.

Cameron et al [17] reported on a series of 422 patients with a diagnosis of shoulder instability and no history of previous shoulder surgery who underwent an arthroscopic procedure. Chondral damage was rated according to the Outerbridge classification system. Of the 88 patients with acute instability (within 90 days of index injury to surgery, average 39.4 days after injury), 24% of the 88 had grade I or higher chondral lesions, 12% had Grade III or IV chondral damage. Of the 334 patients with chronic instability (more than 90 days from the initial injury to surgery and up to 29 years after injury, average 1129 days), 25% had grade I or higher chondral lesions and 12% had Grade III or IV lesions. Although there was no significant difference between patients with acute and chronic instability, there was a statistically significant association between the time from injury to surgery and the presence and grade of chondral damage with a linear trend between time from injury to surgery and the grade of chondral damage. The prevalence of grade III or IV lesions was reported as 15% in patients with anterior instability, 13% in patients with multidirectional instability, and 5% in patients with posterior instability, but the differences were not statistically significant. There was no control group in this study.

Hovellius et al [12] reported a prospective study of 247 first-time anterior shoulder dislocations in 245 patients aged 40 years or younger at the time of dislocation in which 11% of patients had radiographic evidence of mild arthrosis and 9% had radiographic evidence of moderate to severe arthrosis at 10-year follow-up evaluation (Fig. 1). Some patients with only a single dislocation were found to have arthrosis, and the incidence of arthrosis was found to be the same in patients with a single recurrence as in those with multiple dislocations or operative intervention for instability. The authors did not comment on whether patients showed clinical symptoms of shoulder osteoarthritis or if any patients underwent shoulder arthroplasty during the 10-year follow-up.

Neer et al [7] reported that 10% of their series of 273 total shoulder replacements for advanced osteoarthritis were in shoulders with a history of instability, although most of these had undergone previous surgery. Samilson and Prieto [8] described 74 shoulders in 70 patients with radiographic evidence of glenohumeral arthropathy and a history of single or multiple dislocations. They

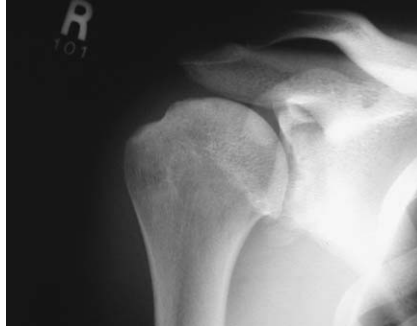

Fig. 1. Osteoarthritis in shoulder of patient with a history of shoulder dislocation.

did not find a significant correlation between the severity of arthrosis and the number of dislocations or a history of surgical treatment for instability, although the severity of arthrosis was associated with limitation of external rotation. A history of posterior dislocation was more common in the shoulders with more severe arthrosis. Gartsman et al [18] reported a series of 83 total shoulder replacements, with six patients (7.2%) reporting a history of instability.

Marx et al [19] investigated the relationship between shoulder dislocation and arthrosis with a case-control study. A total of 91 patients with glenohumeral arthrosis who underwent hemi or total shoulder arthroplasty for osteoarthritis were compared with 282 patients without any history of shoulder symptoms who had undergone total knee arthroplasty. Patients with a history of previous shoulder dislocation were found to have a 19 times greater risk of developing severe shoulder arthrosis than patients who did not have such a history. When patients with a history of shoulder surgery before arthroplasty were excluded, patients had a 10-fold increased risk of developing arthrosis ( $P = 0.003$ ). This analysis did not include the direction of the dislocation.

Matsoukis et al [20] reported on 55 shoulders that had a history of previous anterior dislocation out of a total of 1542 primary total shoulder replacements over 7 years. Of these 55 shoulders, 27 had previously undergone surgery to stabilize the joint while 28 had not undergone any shoulder surgery before the arthroplasty. The authors commented that they did not find any difference between shoulders previously treated with stabilizing surgery and those treated nonoperatively.

To summarize the available data, it is clear that some degree of chondral damage is associated with instability. The articular pathology is likely to worsen with time, although how quickly and in which patients is not well defined. There does appear to be an increased risk of developing symptomatic osteoarthritis and ultimately requiring a shoulder arthroplasty in patients with a history of instability, but again, more study is needed. The other important question is how, if at all, does surgical treatment for instability impact the risk for and progression of glenohumeral osteoarthritis in these patients?

### Association of arthrosis with surgical treatment for instability

Surgical procedures to correct instability are known to put patients at risk for glenohumeral arthritis. The open Bankart, Bristow, Latarjet, Max Lange, Putti-Platt, and other procedures have all been shown to be associated with a risk for glenohumeral arthritis [8,21–28], particularly if the patient loses significant external rotation (Fig. 2).

Brems [9] identifies several factors that may contribute to the development of osteoarthritis after surgical treatment for instability. Inappropriate diagnosis of the direction and degree of instability can lead to a surgical procedure that may not be ideal for a given patient's (true) pathology. Not all instabilities are necessarily anterior or unidirectional. Even with the correct diagnosis, selection of a less optimal procedure perhaps due to surgeon preference, what Brems terms "The Standard Procedure for All," may factor in the subsequent development of arthrosis. Performing the procedure on the wrong side of the joint predisposes to excessive tightness and ultimately arthritis. Intraarticular metal hardware can contribute to the development of osteoarthritis [28]. Finally, the long-term implications of the increasingly popular arthroscopic stabilization instead of open procedures that have a longer track record is yet to be determined. Although the hope is for better long-term outcomes, there is always the risk of unforeseen complicating issues, including an unknown impact on the risk of developing osteoarthritis.

Patients have been known to develop osteoarthritis in both the early and late postoperative periods following surgical treatment for instability [29]. Early postoperative osteoarthritis is often related to hardware [28]. In the series presented by Zuckerman and Matsen, 21 out of 37 patients who developed arthritis of the shoulder were noted to have an instability repair using screws, and an additional 14 patients had undergone instability surgery using staples. Problems developed even in some patients with properly positioned hardware. Metal hardware may break or migrate [30], and thus contribute to osteoarthritic changes (Fig. 3). Early postoperative osteoarthritis ultimately resulting in total shoulder arthroplasty has also been seen after intraarticular extension of a pos-

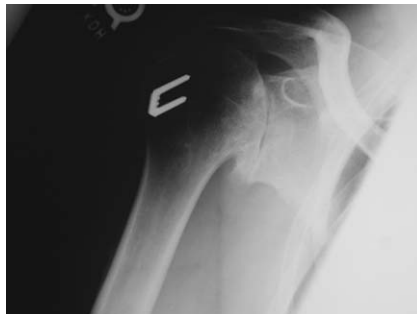

Fig. 2. Patient developed glenohumeral osteoarthritis after previous treatment for shoulder instability.

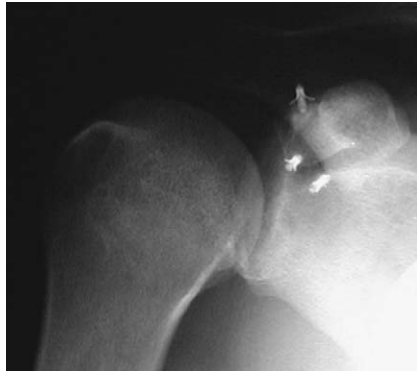

Fig. 3. Suture anchor loose within glenohumeral joint after treatment for shoulder instability.

terior glenoid osteotomy for recurrent posterior instability [31]. If a glenoid osteotomy is necessary, the cut should be made 6 [32] to 10 mm [33] from the articular margin. Bone block procedures have also been associated with the development of osteoarthritis [34,35], probably as a result of impingement on the articular cartilage.

Later onset of shoulder osteoarthritis after instability surgery is associated with excessive restriction of motion [29]. Hawkins and Angelo [21] described a series of 10 patients (11 shoulders) seen an average of 16.8 years after the Putti-Platt procedure with severe degenerative changes. They ascribed the development of osteoarthritis in these shoulders to an excessively tight repair, resulting in altered biomechanics of the glenohumeral joint, generating compression and shear forces on the articular surface. The series of Samilson and Prieto [8] included nine patients who underwent a Putti-Platt procedure, as well as six patients who developed osteoarthritis after a Magnuson-Stack repair, and two after a Bankart repair. They did not report the interval between instability surgery and the diagnosis of arthrosis, but they did note the time from initial dislocation to radiologic diagnosis of arthrosis ranged from 1 to 50 years.

The association between surgical treatment for instability and the subsequent development of osteoarthritis has been demonstrated. But again, rigorous data is lacking. Which patients are at risk and after which procedures? What is the impact of newer arthroscopic procedures on the risk of developing osteoarthritis? Perhaps most importantly, how does surgery change the pathogenesis of osteoarthritis compared with no surgical intervention? Also, the clinical significance of chondral changes following dislocation is unknown.

### **Significance of osteoarthritis after shoulder instability**

The presence of glenohumeral osteoarthritis, particularly on radiograph, does not necessarily translate into clinically significant osteoarthritis. In the 10-year

followup presented by Hovelius et al [12], the only comment on the clinical significance of arthropathy seen radiographically is that the "... patient's subjective assessment of function of the shoulder did not differ significantly..." between the shoulders with and without arthropathy. In the series presented by Cameron et al [17], the authors did not comment on the clinical significance, if any, of the osteoarthritis seen during arthroscopy. The case control study by Marx evaluated patients with arthritis severe enough to require total shoulder arthroplasty. Others have reported on patients who underwent total shoulder arthroplasty and who were noted to have a history of instability or dislocation. More long-term studies are clearly needed to define the relationship between the early onset of radiographically or arthroscopically diagnosed arthritic changes and clinically significant osteoarthritis.

### **Treatment of osteoarthritis after shoulder instability**

Treatment for osteoarthritis after shoulder instability depends on the presentation and etiology of the condition. If metal or a bone block impinging on the articular surface is noticed early, it may be possible to revise before the development of severe arthritis. Arthroscopic debridement, or an arthroscopic or open release in a patient with limited external rotation, are viable options if the patient presents early. Patients who present with advanced osteoarthritis are most often treated with total shoulder replacement if indicated, even in patients presenting at a relatively young age.

If the osteoarthritis is not too advanced, or if the symptoms are mostly mechanical, arthroscopic debridement may be performed [29]. If limited motion is the chief complaint, arthroscopic or open release can provide increased motion and a good result in patients with limited degenerative changes [29,36,37]. The series reported by McDonald et al [38] included 10 patients who developed mild to severe osteoarthritic changes in the glenohumeral joint following an anterior repair for recurrent dislocation. They were treated with release of the subscapularis and noted to have increased external rotation and relief of pain at an average follow-up of 3.5 years. Brems [9] described arthritis of dislocation as an entity presenting in young patients (average age 38) [39] with severe pain and restricted activity. He advocates shoulder arthroplasty (total or hemi based on the condition of the glenoid) as the appropriate treatment once the joint cartilage has been destroyed even in the face of young age. Most authors agree that advanced pain and degenerative change in patients with a history of instability or dislocation warrants shoulder arthroplasty, usually total.

Neer reported excellent or satisfactory results in 17 of 18 patients treated with total shoulder replacement for "arthritis of recurrent dislocation" evaluated at least 24 months after arthroplasty [7]. Young and Rockwood [36] noted relief of pain and functional ROM in all four patients who underwent total shoulder arthroplasty for osteoarthritis following a Bristow procedure for instability. Bigliani et al [40] reported 13 satisfactory results in a series of 17 patients who

underwent shoulder replacement for osteoarthritis after surgery for instability. Sperling et al [41] reported on 31 shoulders in 31 patients with a mean age of 46 years who underwent arthroplasty, 21 total and 10 hemi, for osteoarthritis after instability surgery. Patients noted significant pain relief and improved external rotation and active abduction postoperatively. Eight of the total shoulder arthroplasty patients and three of the hemiarthroplasty patients required revision surgery.

Green and Norris [22] reviewed a series of patients with glenohumeral arthritis and found 39 patients with a history of instability or dislocation, of whom 19 had undergone surgical treatment for anterior instability. Of these 19 patients, 17 underwent shoulder arthroplasty (15 total and 2 hemi). Eleven patients required anterior soft tissue release at the time of arthroplasty (Fig. 4), and four had severe glenoid wear requiring surgical correction. Sixteen of the 17 shoulders were noted to improve after arthroplasty. Three shoulders were noted to require revision after the index arthroplasty.

Matsoukis et al [20] reported on the results of total shoulder arthroplasty in 55 shoulders with a prior anterior shoulder dislocation. Significant improvements in Constant score and ROM were reported, and 50 patients rated the result of their surgery as good or excellent. However, the outcomes were not as good as in patients with primary osteoarthritis. Patients who underwent total shoulder arthroplasty were noted to have a better outcome than patients who underwent hemiarthroplasty. No significant differences were found between shoulders with prior surgical treatment for instability and shoulders without prior surgical treatment.

In general, total shoulder replacement is an appropriate treatment for advanced osteoarthritis arising in shoulders with a history of instability. Outcomes are good, although not as good as in patients with primary osteoarthritis [20,22,40]. Contracture of the anterior soft tissue and erosion of the posterior glenoid are

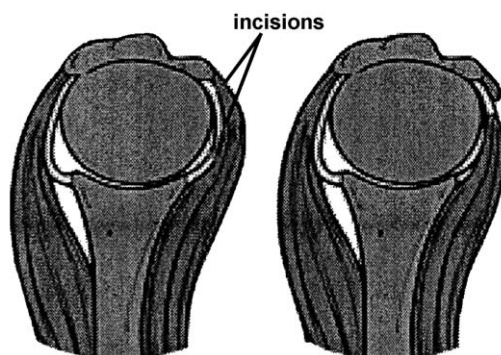


Fig. 4. Anterior soft tissue release during total shoulder arthroplasty (From Marx RG, Craig EV. Primary arthroplasty of the shoulder. In: Chapman MW, et al, editors. Chapman's orthopaedic surgery. 3rd edition. Philadelphia: Lippincott Williams & Wilkins; 2001. p. 2629–64; with permission.)

more common and more severe in patients with a history of previous instability surgery than patients with a history of primary osteoarthritis [9,22,40]. These patients also face a risk of higher rates of revision arthroplasty [41].

## Summary

The relationship between shoulder instability and subsequent glenohumeral osteoarthritis has yet to be clearly defined. There does appear to be an increased risk of osteoarthritis in patients with shoulder instability that tends to occur at a younger age. However, the exact nature of that risk and the clinical implications remain unclear. There is no evidence to support shoulder stabilization surgery for the purpose of preventing glenohumeral osteoarthritis. Patients who develop symptomatic osteoarthritis with soft tissue contracture after instability surgery may benefit from debridement or soft tissue release early, although shoulder arthroplasty is the definitive treatment of choice for advanced symptomatic disease. Arthroplasty is generally successful, although the outcomes are not as satisfactory as in primary osteoarthritis.

## References

- [1] Hovelius L. Incidence of shoulder dislocation in Sweden. *Clin Orthop* 1982;166:127–31.
- [2] Milgrom C, Mann G, Finestone A. A prevalence study of recurrent shoulder dislocations in young adults. *J Shoulder Elbow Surg* 1998;7:621–4.
- [3] Rowe CR. Prognosis in dislocation of the shoulder. *J Bone Joint Surg* 1956;38A:957–77.
- [4] Kazar B, Relovsky E. Prognosis of primary dislocation of the shoulder. *Acta Orthop Scand* 1969;40:216–24.
- [5] Beaty JH. Orthopaedic knowledge update 6. Rosemont (IL): American Academy of Orthopaedic Surgeons; 1999.
- [6] Taylor DC, Arciero RA. Pathologic changes associated with shoulder dislocations. Arthroscopic and physical examination findings in first-time, traumatic anterior dislocations. *Am J Sports Med* 1997;25:306–11.
- [7] Neer CS, Watson KC, Stanton FJ. Recent experience in total shoulder replacement. *J Bone Joint Surg* 1982;64A:319–37.
- [8] Samilson RL, Prieto V. Dislocation arthropathy of the shoulder. *J Bone Joint Surg* 1983; 65A:456–60.
- [9] Brems JJ. Arthritis of dislocation. *Orthop Clin North Am* 1998;29:453–66.
- [10] Hovelius L. Shoulder dislocation in Swedish ice hockey players. *Am J Sports Med* 1978;6: 373–7.
- [11] Hovelius L. Anterior dislocation of the shoulder in teen-agers and young adults. Five-year prognosis. *J Bone Joint Surg Am* 1987;69:393–9.
- [12] Hovelius L, Augustini BG, Fredin H, Johansson O, Norlin R, Thorling J. Primary anterior dislocation of the shoulder in young patients. A ten-year prospective study. *J Bone Joint Surg Am* 1996;78:1677–84.
- [13] Hovelius L, Eriksson K, Fredin H, Hagberg G, Hussenius A, Lind B, et al. Recurrences after initial dislocation of the shoulder. Results of a prospective study of treatment. *J Bone Joint Surg Am* 1983;65:343–9.



- [14] Kazar B, Relovszky E. Prognosis of primary dislocation of the shoulder. *Acta Orthop Scand* 1969;40:216–24.
- [15] Simonet WT, Melton III LJ, Cofield RH, Ilstrup DM. Incidence of anterior shoulder dislocation in Olmsted County, Minnesota. *Clin Orthop* 1984;186:186–91.
- [16] Norlin R. Intraarticular pathology in acute, first-time anterior shoulder dislocation: an arthroscopic study. *Arthroscopy* 1993;9:546–9.
- [17] Cameron ML, Kocher MS, Briggs KK, Horan MP, Hawkins RJ. The prevalence of glenohumeral osteoarthritis in unstable shoulders. *Am J Sports Med* 2003;31:53–5.
- [18] Gartsman GM, Roddey TS, Hammerman SM. Shoulder arthroplasty with or without resurfacing of the glenoid in patients who have osteoarthritis. *J Bone Joint Surg Am* 2000;72:1193–7.
- [19] Marx RG, McCarty EC, Montemurno TD, Altcheck DW, Craig EV, Warren RF. Development of arthritis following dislocation of the shoulder: a case-control study. *J Shoulder Elbow Surg* 2002;11:1–5.
- [20] Matsoukis J, Tabib W, Guiffault P, Mandelbaum A, Walch G, Nemoz C, et al. Shoulder arthroplasty in patients with a prior anterior shoulder dislocation: results of a multicenter study. *J Bone Joint Surg* 2003;85A:1417–24.
- [21] Hawkins RJ, Angelo RL. Glenohumeral osteoarthritis: a late complication of the Putti-Platt repair. *J Bone Joint Surg* 1990;72A:1193–7.
- [22] Green A, Norris TR. Shoulder arthroplasty for advanced glenohumeral arthritis after anterior instability repair. *J Shoulder Elbow Surg* 2001;10(6):539–45.
- [23] Morrey BF, Janes JM. Recurrent anterior dislocation of the shoulder: long-term follow-up of the Putti-Platt and Bankart procedures. *J Bone Joint Surg* 1976;58A:252–6.
- [24] O'Driscoll SW, Evans DC. Long-term results after staple capsulorrhaphy for anterior instability of the shoulder. *J Bone Joint Surg* 1993;75A:249–58.
- [25] Rosenberg BN, Richmond JC, Levine WN. Long-term follow-up of Bankart reconstruction: incidence of late degenerative glenohumeral arthritis. *Am J Sports Med* 1995;23:538–44.
- [26] Singer GC, Kirkland PM, Emery RJ. Coracoid transposition for recurrent anterior instability of the shoulder. A 20-year follow up study. *J Bone Joint Surg Br* 1995;77B:73–6.
- [27] Trevelyn DW, Richardson MW, Fanelli GC. Degenerative joint disease following extracapsular anterior shoulder reconstruction. *Contemp Orthop* 1992;25:151–6.
- [28] Zuckerman JD, Matsen III FA. Complications about the glenohumeral joint related to the use of screws and staples. *J Bone Joint Surg* 1984;66A:175–80.
- [29] Wall MS, Warren RF. Complications of shoulder instability surgery. *Clin Sports Med* 1995;14:973–1000.
- [30] Lyons FA, Rockwood CA. Migration of pins used in operations on the shoulder. *J Bone Joint Surg* 1990;72A:1262–7.
- [31] Johnston GH, Hawkins RJ, Haddad R, et al. A complication of posterior glenoid osteotomy for recurrent posterior shoulder instability. *Clin Orthop* 1984;187:147–9.
- [32] Scott Jr DJ. Treatment of recurrent posterior dislocation of the shoulder by glenoplasty. Report of three cases. *J Bone Joint Surg Am* 1967;49A:471–6.
- [33] English E, Macnab I. Recurrent posterior dislocation of the shoulder. *Can J Surg* 1974;17:147–51.
- [34] Hindmarsh J, Lindberg A. Eden-Hybbinette's operation for recurrent dislocation of the humero-scapular joint. *Acta Orthop Scand* 1967;38:459–78.
- [35] Rockwood Jr CA, Gerber C. Analysis of failed surgical procedures for anterior shoulder instability. *Orthop Trans* 1985;9:48.
- [36] Young CD, Rockwood CA. Complications of a failed Bristow procedure and their management. *J Bone Joint Surg* 1991;73A:969–81.
- [37] Steinman SR, Flatow EL, Pollock RG, Glasgow MD, Bigliani LU. Evaluation and surgical treatment of failed shoulder instability repairs. *Orthop Trans* 1992;16:727.
- [38] MacDonald PB, Hawkins RJ, Fowler PJ, Miniaci A. Release of the subscapularis for internal rotation contracture and pain after anterior repair for recurrent anterior dislocation of the shoulder. *J Bone Joint Surg Am* 1992;74:734–7.

- [39] Brems JJ. Shoulder replacement in arthritis of dislocation. *Orthoped Trans* 1989;13:235.
- [40] Bigliani LU, Weinstein DM, Glasgow MT, Pollock RG, Flatow EL. Glenohumeral arthroplasty for arthritis after instability surgery. *J Shoulder Elbow Surg* 1995;4(2):87–94.
- [41] Sperling JW, Antuna SA, Sanchez-Sotelo J, Schleck C, Cofield RH. Shoulder arthroplasty for arthritis after instability surgery. *J Bone Joint Surg* 2002;84A(10):1775–81.