

Calcific Tendinitis

Seth L. Sherman, MD

Robert G. Marx, MD

Introduction

Calcific tendinitis is a common disorder of the shoulder in which multifocal, cell-mediated calcification in or around a living tendon is usually followed by spontaneous phagocytic resorption.¹ The tendon reconstitutes itself after resorption or surgical removal of the calcium deposit.² Although the etiology of calcific tendinitis remains controversial, circumscribed tissue hypoxia and localized tissue pressure may be triggers for the disease process.^{2,3} In some patients with calcific tendinitis, acute or chronic pain is caused by inflammation around the calcium deposits.² Mild or moderate chronic pain may be present during the formative, calcium deposition phase, although this phase is latent and asymptomatic in most patients. The acute, resorptive phase may be characterized by an abrupt onset of severe pain that limits function. The pain may be caused by inflammation or secondary to rotator cuff impingement from bursal irritation, thickening, or deposit prominence. Chronic glenohumeral stiffness can also result from calcific tendinitis.

Epidemiology

Most patients with calcific tendinitis are 30 to 50 years old, and women are affected approximately 1.5 times as often as men.^{2,4} As many as 10% of patients have bilateral deposits. The reported incidence ranges from 2.7% to 63% of the general population; it varies with the clinical and radiographic criteria used in the study.⁵ More than 30% of patients with insulin-dependent diabetes mellitus develop tendon calcification;² patients with diabetes are more likely than other patients to have asymptomatic deposits. Approximately 25% of patients with calcific tendinitis have a rotator cuff tear, although these patients are likely to have a relatively small amount of calcification.² In approximately 80% of patients, the disease occurs in the supraspinatus tendon, 1.5 to 2 cm from the tendinous insertion at the greater tuberosity.^{2,4} There may be a genetic susceptibility to calcific tendinitis; patients were found to have an increased frequency of the HLA-A1 antigen.¹

Pathogenesis

The mechanism of calcific tendinitis was first believed to involve degenerative calcification. This theory held that tendon fiber degeneration precedes calcification in the critical zone at the hypovascular bone-tendon junction.⁶ Age-related wear leads to tendon fiber degeneration, followed by focal hyalinization, fibrillation, and eventual detachment from the surrounding normal tendon fibers.^{1,2} The necrotic debris becomes calcified in a process that corresponds histologically with necrosis of tenocytes and intracellular accumulation of calcium in the form of microspheroliths or psammomas.

More recent studies have rejected the degenerative calcification model and proposed reactive calcification as the mechanism.^{1,2} These studies point out that the degenerative calcification model has several limitations. It fails to consider that incidence does not increase with patient age (the typical patient is in the fifth decade of life); that the disease is self-limiting; and that the histologic, morphologic, and ultrastructural features of

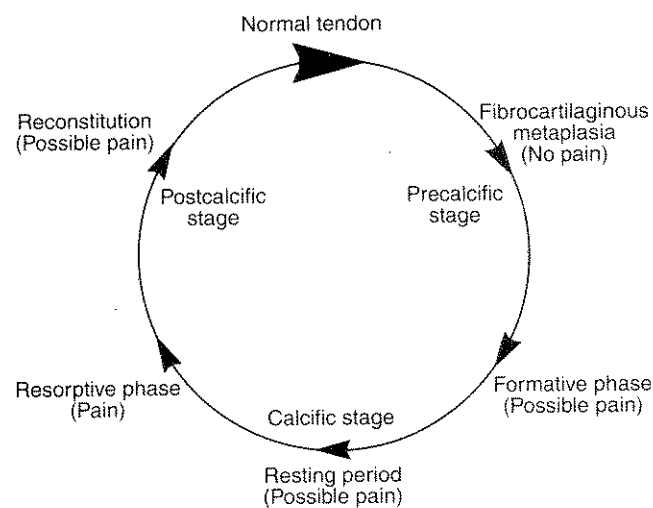


Figure 1 Schematic representation of the progressive phases of calcific tendinitis. (Adapted from Uhthoff HK, Loehr JW: Calcific tendinopathy of the rotator cuff: Pathogenesis, diagnosis, and management. *J Am Acad Orthop Surg* 1997;5:183-191.)

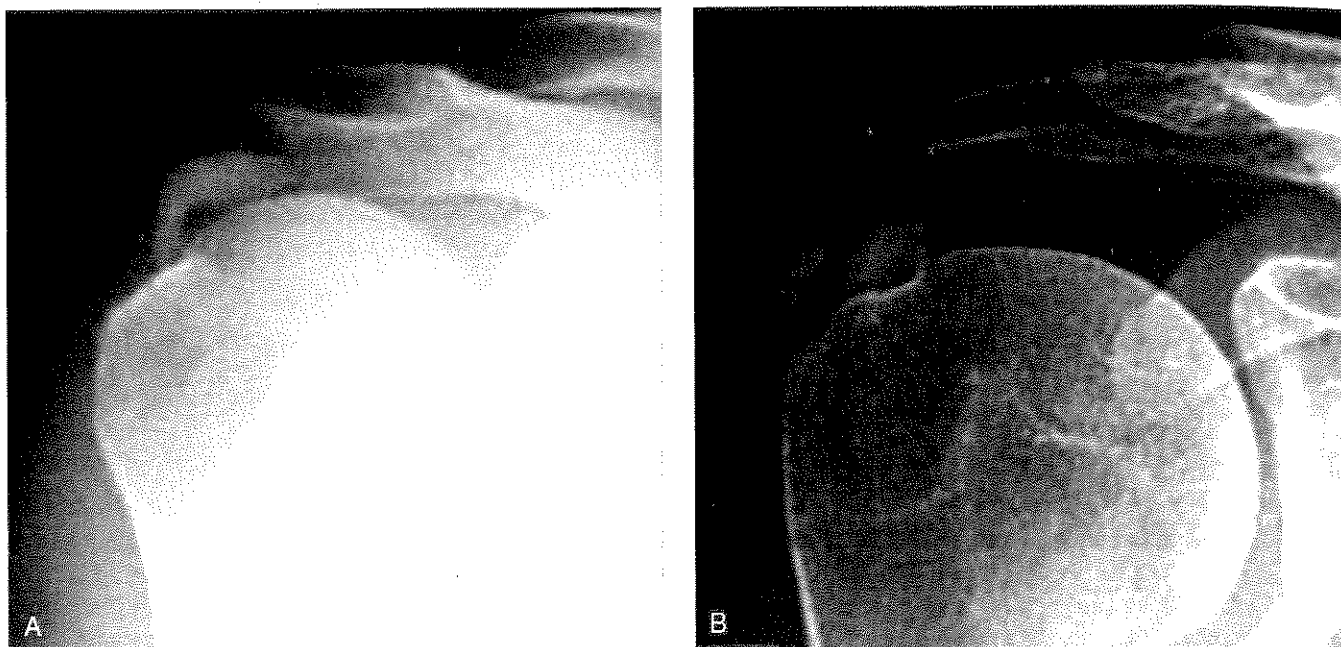


Figure 2 AP radiographs showing calcifications. **A**, Dense, rounded, and sharply delineated calcification (DePalma type II, Gärtner type III). **B**, Multilobar, radiodense, and sharply delineated calcification (Gärtner type II). (Reproduced with permission from Porcellini G, Paladini P, Campi F, Paganelli M: Arthroscopic treatment of calcifying tendinitis of the shoulder: Clinical and ultrasonographic follow-up findings at two to five years. *J Shoulder Elbow Surg* 2004;13:503-508.)

degenerative calcification are different from those observed in patients with calcific tendinitis. In addition, the model does not differentiate between insertional tendon calcification and intrasubstance calcification.¹

The active mediation of calcification by cells in a viable environment is called reactive calcification.^{1,2} The process has three stages (Figure 1). During the first, pre-calcific stage, the predisposed site undergoes fibrocartilaginous metaplasia of tenocytes into chondrocytes. The second, calcific stage has three phases: formative, resting, and resorptive. During the formative phase, calcium crystals are deposited primarily in matrix vesicles, which coalesce to form large foci of calcification. These appear in multifocal areas within the tendon and are separated by fibrocartilaginous or fibrocollagenous tissue. The deposits have a chalklike consistency.^{1,2} The resting phase begins when calcium deposition ends and the fibrocartilaginous tissue bordering the foci of calcification shows no evidence of inflammation.² After a variable period of inactivity, the resorptive phase begins with the appearance of thin-walled vascular channels at the periphery of the calcium deposits. Macrophages and multinucleated giant cells surround the deposits and phagocytose debris as the calcium is resorbed. Morphologically, the material is formed by inflammatory cell-mediated breakdown of the calcium deposit during the formative phase; it forms a thick, creamy material under pressure during the resorptive phase. During the final, postcalcific stage, granulation tissue with young fibroblasts and new vascular channels remodels the space occupied by

the resorbing calcium deposits. With scar maturation, type III collagen is replaced with type I collagen. The tendon heals with subsequent fiber realignment.^{1,2}

The reactive calcification theory describes the pathogenesis of the disease based on morphologic studies. However, the factors causing the initial fibrocartilaginous transformation within the tendon and the factors leading to the onset of the resorptive period remain elusive.

Classification

The DePalma and Kruper classification describes two radiographic types, which are clinically correlated with the resorptive and formative phases. Type I, usually seen during the resorptive phase in patients with acute pain, has a fluffy, fleecy appearance with a poorly defined periphery; an overlying crescentic streak indicates rupture of the calcium deposit into the subacromial bursa. Type II corresponds to subacute or chronic disease in the formative phase and is characterized by discrete, homogenous deposits with uniform density and a well-defined periphery. Radiographic change can be seen from type II to type I but never from type I to type II^{1,7,8} (Figure 2).

The commonly used Gärtner classification system is also based on the radiographic appearance of the calcification. Type I is homogenous in structure and has well-defined borders; type II is heterogeneous with a sharp outline or homogenous without a defined border; and type III is cloudy and translucent⁸ (Figure 3).

Clinical Evaluation

Calcific tendinitis is usually diagnosed by a thorough patient evaluation that includes a detailed history, a focused physical examination, and basic radiographic studies.⁶ The initial radiographs should include AP, internal and external rotation, scapular Y, and axillary views to determine the location of the deposits and reveal possible impingement.² Supraspinatus tendon deposits can be seen on a neutral rotation view; infraspinatus or teres minor deposits, an internal rotation view; and subscapularis tendon deposits, an external rotation view.¹ The scapular Y view can help in determining whether the calcification is causing impingement. CT can be useful if the calcium deposits are not clearly visible on plain radiographs. On T1-weighted MRI images, calcium deposits appear as areas of decreased signal intensity. T2-weighted images frequently reveal a perifocal band of increased signal intensity consistent with edema.¹ MRI can also be helpful in determining the presence of an associated rotator cuff tear.

It is important to distinguish calcific tendinitis from a rotator cuff tear because the treatment of the two conditions is inherently different.⁶ The clinical presentation of calcific tendinitis depends on the stage and extent of disease. The formative phase is rarely symptomatic.³ Acute symptomatic episodes usually occur during the resorptive phase because of edema and the sudden increase in intratendinous pressure.³ For approximately 50% of patients diagnosed during the resorptive phase, the primary complaints are shoulder pain, especially at night, and decreased range of motion.⁵ On radiographs, these patients have cloudy, translucent tendon calcification without clear circumscription (DePalma type I, Gartner type III). The patients with the worst pain and symptoms usually have the best prognosis, for reasons that are not entirely clear. It is possible that robust acute inflammation more readily clears the deposits and leads into the postcalcific healing phase.

There is a strong tendency to self-healing by spontaneous resorption of the deposits. Within approximately 2 to 3 weeks of the onset of symptoms, the patient usually regains a normally functioning joint, with or without treatment. However, the condition does not always follow this pattern, and the natural cycle can be blocked at any point.⁹ In these patients, the symptoms are related to the presence of dense, sharply delineated calcifications (DePalma type II, Gartner types I and II) that can become chronic and debilitating.⁵ The calcification sometimes leads to a rotator cuff tear.⁹ Although the symptoms disappear as the calcification disappears, the time required for spontaneous resolution of calcification and the related symptoms often represents an unacceptably long interference with the patient's quality of life. In one study, calcifications disappeared in 9.3% of patients within 3 years of the initial diagnosis.¹⁰ In another

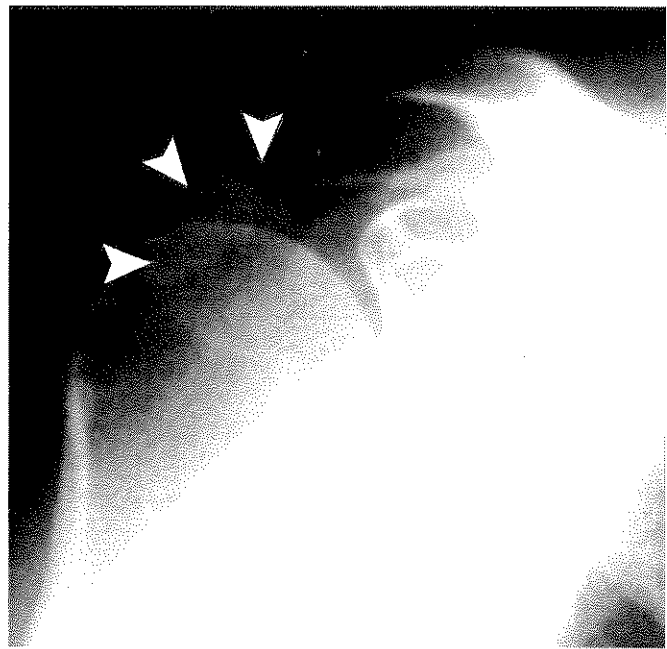


Figure 3 AP radiograph showing fluffy, indistinct calcification (arrowheads) corresponding to Gartner type III. (Reproduced with permission from Hurt G, Baker CL Jr: Calcific tendinitis of the shoulder. *Orthop Clin North Am* 2003;34:567-575.)

study, calcifications disappeared in 27.1% of patients within 10 years.¹¹ A third study reported that calcifications with sharp margins and a homogeneous or heterogeneous structure disappeared spontaneously in 33% of patients within 3 years.¹²

Treatment

Proper treatment of calcific tendinitis of the rotator cuff requires distinguishing between the resorptive and formative phases. The goals of treatment are pain reduction and the disappearance of calcium deposits. Physical therapy, oral nonsteroidal anti-inflammatory drugs (NSAIDs), subacromial corticosteroid injections, needle lavage, and extracorporeal shock-wave therapy (ESWT) are the mainstays of nonsurgical treatment of acute and chronic disease. Open or arthroscopic surgery is reserved for patients who had unsuccessful nonsurgical treatment.

The Resorptive Phase (Acute Calcific Tendinitis)

In a patient who has clinical and radiographic signs of the resorptive phase (severe, acute-onset shoulder pain; decreased range of motion; Gartner type III radiographic findings), spontaneous resolution of the disease can be anticipated.¹ The treatment of these patients should be focused on controlling pain, decreasing inflammation, relieving intratendinous pressure, and maintaining range of motion. Steroid injections are effective in decreasing pain and inflammation for patients with acute symptoms, although there is no evidence that

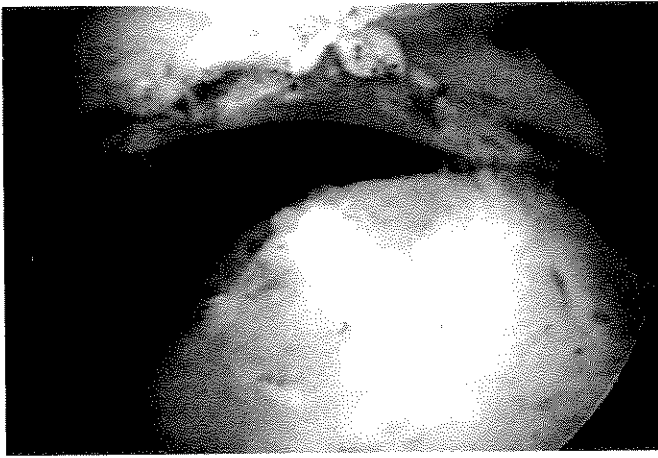


Figure 4 Arthroscopic view of the bursal side showing evidence of a calcific deposit in the rotator cuff tendon. (Reproduced with permission from Hurt G, Baker CL Jr. *Calcific tendinitis of the shoulder*. *Orthop Clin North Am* 2003;34:567-575.)

steroid injections facilitate calcium resorption¹³ and frequent injections may be harmful to the tendon structure.⁶ A short course of NSAIDs is often useful in pain control, although there is no evidence that they alter the natural progression of the disease.^{1,13}

During the resorptive phase of calcific tendinitis, the use of treatments such as ESWT, radiotherapy, and arthroscopic and open surgical procedures is not indicated. Supportive measures and gentle physical therapy to maintain range of motion usually lead to a favorable outcome.

Needle lavage is often extremely useful during the resorptive stage to decrease intratendinous pressure.² Lavage is performed in the operating room or radiology suite. The preferred technique uses an inflow-outflow setup with two large-bore needles and injection of 2% lidocaine.¹ The clinical response to needle lavage has been favorable; in one study, more than 70% of patients had improvement in pain.² Needle aspiration and lavage using ultrasonography or image intensification was reported to eliminate between 28% and 76% of calcium deposits.⁴ Most calcifications are likely to be resorbed spontaneously, without intervention, in patients with acute symptoms. Therefore, completely eliminating deposits with needle lavage is less important than decreasing intratendinous pressure and pain.

The Formative Phase (Chronic Calcific Tendinitis)

Chronic, debilitating calcific tendinitis has been the focus of much recent research. Patients with chronic, debilitating calcific tendinitis are in the formative phase of the disease, with Gärtner type I or type II radiographic findings. Although the natural history of calcification is unclear in these patients, spontaneous resolution does not usually occur. Standard nonsurgical treatments have been unsuccessful. Treatments ranging from ESWT to

open and arthroscopic surgery have been used to address patients' functional concerns.

ESWT is gaining popularity as a treatment for chronic calcific tendinitis of the rotator cuff. Sound waves are used to create substantial differences in pressure at the interface of anatomic structures having different acoustic impedances.¹⁴ Although the mechanism of action is not fully understood, ESWT has been used to target calcium deposits for resorption. A recent review of 16 studies, including 5 randomized controlled trials, found moderate evidence that high-energy ESWT is effective for chronic calcific tendinitis when the shock waves are focused on the calcium deposit.¹⁵ High-energy ESWT was found to be superior to low-energy ESWT or placebo treatment, and ESWT was found more effective than transcutaneous electrical nerve stimulation.^{15,16} The clinical and radiographic outcomes of ESWT appear to be significantly better when three-dimensional computer-assisted navigation is used to locate the calcium deposit.¹⁴ Another recent randomized, controlled study found that, in comparison with ESWT alone, ultrasonography-guided needle lavage in combination with high-energy ESWT significantly improved calcium deposit elimination, led to better clinical results, and decreased the need for surgery.⁴ All of these studies suggest a relationship between residual calcium deposits and eventual clinical outcome, but this relationship has yet to be fully explored.

Surgical treatment of calcific tendinitis is most helpful for patients who are in a chronic formative phase, especially if impingement symptoms are present. Approximately 10% of all patients have shoulder pain that is unresponsive to nonsurgical treatment and requires surgical treatment.² Open or arthroscopic excision of calcium deposits reliably leads to pain relief.³ The indications for surgery include symptom progression, constant pain that interferes with activities of daily living, and lack of improvement after nonsurgical treatment.² Open surgical procedures have had very good results. Studies have consistently found that 82% to 88% of patients rate the subjective outcome as excellent; the improvement in the Constant score is as much as 100%.³ The outcomes of recent arthroscopic surgical procedures appear to be equivalent to those of open procedures. Arthroscopic surgery offers better cosmesis, a shorter length of stay, and a shorter rehabilitation time without compromising patient outcome, and it has become the preferred method of surgical treatment for calcific tendinitis¹ (Figures 4 and 5). Studies of arthroscopic removal of rotator cuff calcifications found that 79% to 94% of patients had excellent shoulder function and subjective satisfaction; the average age- and gender-corrected Constant scores were 85 points or higher.³

The arthroscopic treatment of calcific tendinitis is technically demanding. It can be difficult to locate the calcium deposits within the tendon and determine the

amount of resection needed, while avoiding compromise of the surrounding healthy tendon. Postsurgical recovery requires 3 to 6 months because the tendon and subacromial bursa heal slowly. Pain relief is gradual and progressive, and it may extend over the entire first year. Nonetheless, most patients are able to return to work within 6 weeks.³ Complications of the arthroscopic technique, although uncommon, have been reported to include frozen shoulder, hematoma, and residual impingement because of inadequate resection (requiring repeat surgery and possible subacromial decompression).^{3,17} The amount of calcium deposit for which resection is necessary, the use of subacromial decompression acromioplasty, and the routine exploration of the glenohumeral joint are controversial topics in arthroscopic treatment.

The reported rates of complete calcium deposit removal range from 40% to 88%.³ A large study with a 2-year follow-up found that a successful outcome depended only on the absence of calcium deposits, and a high Constant score was inversely related to the number and size of residual calcium deposits.⁹ The complete removal of all calcifications was therefore recommended.

Another large study found that more than 90% of patients had excellent shoulder function and satisfaction at 2-year follow-up, although only 44% had immediate and complete removal of calcification.³ The study concluded that complete removal of calcification is not absolutely necessary, and partial resection, with preservation of surrounding healthy tendon, is sufficient for an excellent functional outcome. Prospective, randomized studies are needed to settle the ongoing debate.

Studies of routine subacromial decompression found that good results were obtained regardless of whether subacromial decompression was used.^{3,9,18} Some surgeons argue that decompression is not routinely indicated because it does not improve outcomes and leads to a moderate decrease in postsurgical strength.⁹ In general, it has been suggested that subacromial decompression should be performed if intrasurgical signs of mechanical irritation appear on the undersurface of the acromion or the calcium deposits cannot be completely removed without causing significant tendon damage.³ For patients with obvious inflammatory changes around a calcium deposit or with large deposits that bulge into the subacromial space and cause obvious mechanical impingement, acromioplasty is not routinely indicated because it does not address the underlying condition.

Routine exploration of the glenohumeral joint is often part of the arthroscopic treatment of calcific tendinitis, although the deposits are removed through a bursal approach. Few studies have addressed the desirability of entering the joint. At 3-month follow-up, duration of pain and time to return to work were found to be significantly greater in patients who underwent routine glenohumeral exploration; however, Constant scores and re-

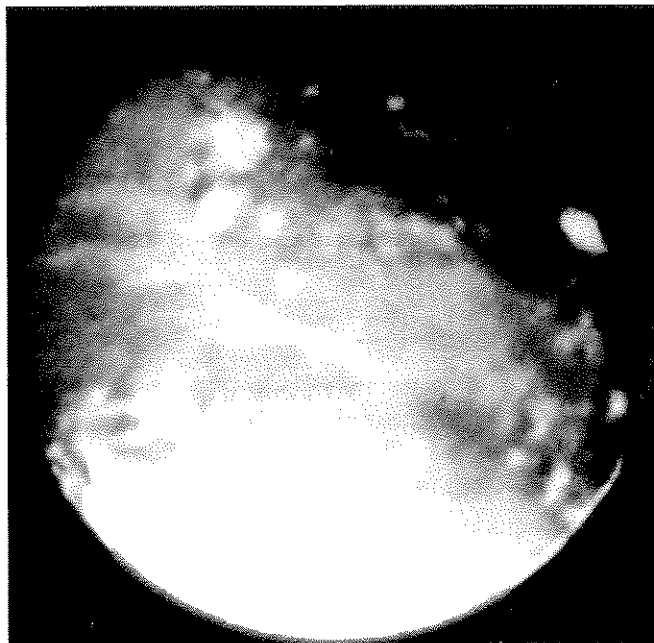

Figure 5 Arthroscopic view showing the snowstorm effect, which is often seen with arthroscopic needle lavage or débridement of calcific tendinitis. (Reproduced with permission from Hurt G, Baker CL Jr. Calcific tendinitis of the shoulder. *Orthop Clin North Am* 2003;34:567-575.)

sidual deposit size were not affected at 6-month follow-up.¹⁸ Although a larger prospective evaluation is needed, routine glenohumeral exploration appears to be detrimental to short-term outcome and not essential in the arthroscopic treatment of calcific tendinitis.

Summary

Calcific tendinitis is a common shoulder disorder of unknown etiology that involves calcium deposition and resorption within a rotator cuff tendon. Most affected patients are 30 to 50 years old. Most calcifications occur 1.5 to 2 cm from the insertion of the supraspinatus tendon. Calcific tendinitis is a process of reactive formation involving three stages: precalcific, calcific (formative, resting, and resorptive), and postcalcific. The diagnosis is made through patient history, physical examination, and imaging studies. Patients in the resorptive phase may have acute-onset shoulder pain, decreased range of motion, and Gärtner type III calcium deposits. These patients are best treated using NSAIDs, subacromial injections, gentle physical therapy, and, for some patients, needle lavage. Spontaneous resolution with subsequent tendon healing usually occurs within 2 to 3 weeks. Patients in the formative phase may have chronic, progressive shoulder pain and Gärtner type I or type II deposits. High-energy ESWT, with or without ultrasonography-guided needle lavage, has been successful in these patients. For 10% of patients, surgery is indicated after unsuccessful nonsurgical treatment.

Open and arthroscopic procedures have had equivalent outcomes (patient satisfaction 79% to 94%, Constant score > 85). Arthroscopic treatment offers improved cosmesis, a shorter hospital stay, and a shorter rehabilitation period. Controversies in arthroscopic treatment include the amount of calcium deposit resection necessary for functional improvement, the use of routine subacromial decompression, and the benefit of glenohumeral joint exploration.

Annotated References

1. Uthoff HK, Loehr JW: Calcific tendinopathy of the rotator cuff: Pathogenesis, diagnosis, and management. *J Am Acad Orthop Surg* 1997;5:183-191.

2. Hurt G, Baker CL Jr: Calcific tendinitis of the shoulder. *Orthop Clin North Am* 2003;34:567-575.

This comprehensive review discusses the pathogenesis, radiographic evaluation, and nonsurgical and surgical treatment of calcific tendinitis.

3. Seil R, Litzenger H, Kohn D, Rupp S: Arthroscopic treatment of chronically painful calcifying tendinitis of the supraspinatus tendon. *Arthroscopy* 2006;22:521-527.

Fifty-four patients, mean age 45.4 years, underwent arthroscopic removal of calcific tendinitis of the supraspinatus. At 24-month follow-up, the mean Constant score improved from 32.8 to 90.9. Thirty-one percent were pain free or had achieved maximum pain relief at 3 months; 28% had achieved maximum pain relief at 12 months. Seventy-eight percent returned to work within 6 weeks, and 92% were satisfied with the outcome. Complete removal of the deposits did not appear to be essential.

4. Krasny C, Enenkel M, Aigner N, Wlk M, Landsiedl F: Ultrasound-guided needling combined with shock-wave therapy for the treatment of calcifying tendinitis of the shoulder. *J Bone Joint Surg Br* 2005;87:501-507.

A prospective, randomized controlled trial compared ESWT with ultrasonography-guided needling followed by high-energy ESWT for the treatment of chronic calcific tendinitis of the shoulder. Forty patients received each treatment, and the mean follow-up time was 4.1 months. The combined treatment led to a disappearance of deposits in 60% of patients and avoidance of surgery in 80%, compared with 32.5% and 55%, respectively, in patients who received only ESWT. The patients who received the combined treatment also had significantly better clinical results.

5. Cacchio A, Paoloni M, Barile A, et al: Effectiveness of radial shock-wave therapy for calcific tendinitis of the shoulder: Single-blind, randomized clinical study. *Phys Ther* 2006;86:672-682.

Calcifications disappeared completely in 86% of 90 patients who received radial shock-wave therapy and partial-

ly disappeared in 13.4%. Only 8.8% of the control-group patients had partial disappearance of calcifications, and none had total disappearance. Radial shock-wave therapy led to a significant reduction in pain and improved shoulder function after 4 weeks.

6. Moretti B, Garofalo R, Genco S, Patella V, Mouhsine E: Medium-energy shock wave therapy in the treatment of rotator cuff calcifying tendinitis. *Knee Surg Sports Traumatol Arthrosc* 2005;13:405-410.

Fifty-four patients with calcific tendinitis underwent medium-energy ESWT. At 1-month and 6-month follow-ups, 70% had a satisfactory functional result. The deposits disappeared in 54% and were less than half the original size in 35%. No complications were reported.

7. DePalma AF, Kruper JS: Long-term study of shoulder joints afflicted with and treated for calcific tendinitis. *Clin Orthop Relat Res* 1961;20:61-72.

8. Gärtner J, Heyer A: [Calcific tendinitis of the shoulder.] *Orthopade* 1995;24:284-302.

9. Porcellini G, Paladini P, Campi F, Paganelli M: Arthroscopic treatment of calcifying tendinitis of the shoulder: Clinical and ultrasonographic follow-up findings at two to five years. *J Shoulder Elbow Surg* 2004;13:503-508.

Ninety-five shoulders (63 patients) underwent clinical and ultrasonographic evaluation at a mean 36-month follow-up after arthroscopic treatment of calcific tendinitis. Ultrasonography revealed no cuff tears. At 24-month follow-up, the Constant score was inversely related to the number and size of residual calcifications in all patients. Outcome was strongly related only to the presence of residual calcification, and complete removal of deposits was therefore recommended.

10. Bosworth BM: Calcium deposits in the shoulder and subacromial bursitis: A survey of 12,122 shoulders. *JAMA* 1941;116:2477-2482.

11. Wagenhauser JF: Die periartropatie-syndrome. *Therapiewoche* 1972;37:3187-3192.

12. Gärtner J: [Tendinosis calcarea: Results of treatment with needling.] *Z Orthop Ihre Grenzgeb* 1993;131:461-469.

13. Vad VB, Solomon J, Adin DR: The role of subacromial shoulder irrigation in the treatment of calcific rotator cuff tendinosis: A case series. *Arch Phys Med Rehabil* 2005;86:1270-1272.

Twenty-eight patients underwent fluoroscopy-guided subacromial shoulder irrigation followed by corticosteroid injection for the treatment of chronic calcific tendinitis after unsuccessful nonsurgical treatment. At 1-year follow-up, 85.7% had significantly improved satisfaction, as measured using the L'Insalata Shoulder Rating Questionnaire and visible numeric pain score.

14. Sabeti-Aschraf M, Dorotka R, Goll A, Trieb K: Extracorporeal shock wave therapy in the treatment of calcific tendinitis of the rotator cuff. *Am J Sports Med* 2005;33:1365-1368.

A prospective, randomized single-blind study of 50 patients compared the use of low-energy ESWT and three-dimensional computer-assisted navigation with the use of ESWT and patient-to-therapist feedback. Patients in both groups had significantly improved Constant-Murley and visual analog scores at 12-week follow-up, although the results were significantly better in the patients who had received ESWT and computer-assisted navigation.

15. Harniman E, Carette S, Kennedy C, et al: Extracorporeal shock wave therapy for calcific and noncalcific tendonitis of the rotator cuff: A systematic review. *J Hand Ther* 2004;17:132-151.

This review of 16 studies, including 5 randomized controlled studies, found moderate evidence that high-energy ESWT is effective for chronic calcific tendinitis of the shoulder if the shock waves are focused at the calcific deposit.

16. Gerdsmeyer L, Wagenpfeil S, Haake M, et al: Extracorporeal shock wave therapy for the treatment of chronic calcifying tendonitis of the rotator cuff: A randomized controlled trial. *JAMA* 2003;290:2573-2580.

A randomized, controlled double-blind study compared the use of high-energy ESWT, low-energy ESWT, and placebo treatment for chronic calcific tendinitis. Both high-energy and low-energy ESWT had a beneficial effect on shoulder function and patient-rated pain score. Both re-

sulted in decreased calcification size at 3-, 6- and 12-month follow-up, compared with placebo treatment. High-energy ESWT appeared to provide better results than low-energy ESWT.

17. Jacobs R, Debeer P: Calcifying tendinitis of the rotator cuff: Functional outcome after arthroscopic treatment. *Acta Orthop Belg* 2006;72:276-281.

Sixty-one shoulders were treated with arthroscopic excision, subacromial bursa débridement, and shaving. At a mean 15-month follow-up, modified Constant and Disabilities of the Arm, Shoulder and Hand scores significantly improved (from 33.4 to 66.8 and from 49.7 to 17.3, respectively). Acromioplasty or residual calcification did not affect final outcome. Frozen shoulder occurred in 18%. Level of evidence: IV.

18. Sirveaux F, Gosselin O, Roche O, Turell P, Molé D: Postoperative results after arthroscopic treatment of rotator cuff calcifying tendonitis, with or without associated glenohumeral exploration. *Rev Chir Orthop Reparatrice Appar Mot* 2005;91:295-299.

In a retrospective study of 64 patients treated arthroscopically for chronic calcific tendinitis of the rotator cuff using a bursal approach either in isolation or with glenohumeral exploration, no difference in Constant score or deposit disappearance was found at 6-month follow-up. The average duration of pain and time to return to work (11 weeks and 12 weeks, respectively) were significantly higher in patients who underwent glenohumeral exploration, compared with the remaining patients (6 weeks and 5 weeks, respectively).